ILLUSTRATIONS

OF

MR. S. COOPER'S

SURGICAL DICTIONARY.

BY W. P. COCKS,

SURGEON.

LONDON:

PUBLISHED BY LONGMAN, REES, AND CO.,

PATERNOSTER-ROW.

1831.

HARJETTE AND SAVILL, PRINTERS,
107, ST. MARTIN'S LANE, CHARING CROSS.

ADVERTISEMENT.

THIS Volume of Illustrations is presented to the medical profession without preface or apology.

The necessity of a work of this kind has long been felt in this country; but the difficulty and expense necessarily attendant on the execution of it have hitherto prevented any attempt to fill up the chasm in our medical libraries. The subjects introduced have been carefully selected from the works of the best English, as well as those of the French, German, and Italian authorities, accompanied by a great many Original Sketches.

The Author intends to complete the work in three volumes. These will embrace the whole of Surgical Pathology, with the various operations, forming a magazine of surgical science. The following subjects will be completed in volume the second:—Amputations; Aneurisms; Anus Diseases; Bandages; Burns; Bladder Diseases;

Bleeding; Cancers; Carbuncles; Cataracts and Diseases of the Eye in general; Dislocations, Fractures, and Diseases of the Bones; Ear, and its Diseases, Erysipelas, and several Diseases of the Skin; Gangrene; Hare-lip; and Diseases of the Œsophagus. The plates are so arranged that the collator will have very little trouble in placing them in their respective places when the second volume is finished, if he follows the alphabetical order pursued in the work. A copious index will accompany each volume when the work is completed.

London, 1831.

CONTENTS.

AMPUTATIONS.

SURGICAL ANATOMY OF THE HEAD AND NECK.

BANDAGES.

CANCERS.

DISLOCATIONS.

FRACTURES.

DISEASES OF THE BONES.

GUN-SHOT WOUNDS.

HERNIÆ.

SUPPLEMENT.

TUMOURS.

TUMOURS FROM AN INFILTRATION OF FLUID.

EXCRESCENCES.

Such an operation frequently becomes indispensably proper, on the principle of sacrificing a branch, as it were, for the sake of taking the only rational chance of saving the trunk itself. Indeed, the suggestion of this measure in cases of mortification, where there is no chance of the parts recovering, may be said to be derived from nature herself, who, by a certain process, detaches the dead from the living parts: this separation is followed by cicatrization, and the patient recovers.

The necessity for amputation has always existed, and ever will continue, as long as the destructive effects of injuries and diseases of the limbs cannot be obviated in any other manner; although it is much less frequently performed at present, than it was forty years ago.

PLATE A. 1.

Fig. 1.

This sketch shews the manner in which the subclavian artery is compressed in amputation at the shoulder-joint. The compression is here made with the handle of the tourniquet, but a common key would answer the purpose.

Fig 1.

Fig 2.

W.P. Cocks.

PLATE A. 1.

---

*Amputation at the Shoulder-Joint.**

Fig. 2.

The operator makes a longitudinal incision, which begins at the acromion, and extends downwards about an inch below the neck of the humerus, dividing the integuments and the deltoid muscle into two equal halves. The skin of the arm is then to be pulled up towards the shoulder by an assistant, and the anterior and posterior flaps are to be formed by two oblique incisions, made from within outwards, and at the same time downwards, care being taken that the tendons of the pectoralis major and latissimus dorsi are divided.

No fear need be entertained of wounding the axillary vessels, which are out of the reach of the point of the knife. The cellular adhesions of the two flaps are now to be cut through, and the flaps themselves lifted up by an assistant, who must also compress the divided circumflex arteries.

* Baron Larrey.

Thus the shoulder-joint becomes freely exposed. The knife is then to be conducted round the head of the bone, so as to divide the capsular ligament and tendons of muscles belonging to the joint; the head of the bone is next to be inclined a little outwards, and the knife carried down close to the posterior surface of the humerus, for the purpose of completing the division of the tendinous and ligamentous connexions situated in that direction.

An assistant then compresses the axillary artery between his two fore-fingers, and commands the flow of blood through it, while the surgeon turns the edge of the knife backwards, and cuts through the axillary vessels opposite the lower angles of the two flaps, and just in front of the fingers of the assistant; without remitting the pressure, the axillary artery is readily taken up with a pair of forceps and tied.

All that afterwards remains to be done, is to secure the circumflex arteries.

The wound having been cleaned with a sponge, the flaps are to be lightly brought together with two or three straps of adhesive plaster, (see fig. 3. plate 1. *a*.) over which the other dressings and a bandage are to be put, according to the rules observed after amputations in general.

Fig 1.

Fig 2.

Fig 3.

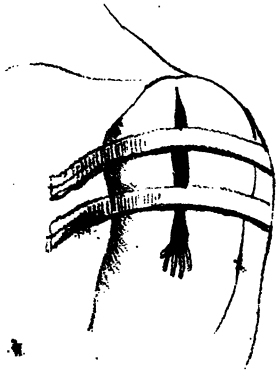

PLATE A. 1. *a*.

---

*Amputation at the Shoulder-Joint.**

Fig. 1.

The operator, standing on the outside of the patient, makes a transverse incision at the upper and outer part of the arm, about three inches below the acromion. The wound is thus carried completely through the deltoid down to the humerus. This having been done, a longitudinal cut is to be made from the point opposite the coracoid process to the anterior extremity of the transverse incision, and this second cut must also divide the deltoid down to the bone. A third incision is to be made behind, reaching from the place where the acromion unites with the spine of the scapula to the posterior termination of the transverse wound. In this way, a square flap is formed that comprises nearly the whole of the deltoid. It is next to be separated from the humerus, and

* M. Richerand.

raised, so that the shoulder-joint may be got at. The posterior circumflex artery may now be found in the back angle of the wound, and as soon as it has been tied, the tendons of the teres minor and of the supra and infra-spinatus muscles are to be cut through. Then the arm is to be allowed to hang down, and rotated outwards, for the purpose of making the subscapularis muscle tense, which is to be divided. The next thing is to open the capsular ligament extended over the head of the bone, and at the same time to cut through the tendons, the long head of the biceps, and, after dividing the capsule more freely, to dislocate the head of the humerus upwards and outwards. The large knife is now to be laid aside, and a straight bistory applied to the inside of the humerus, along which it is to be carried downwards, so as to separate the soft parts from it sufficiently far down the limb; but previously to completing the inner flap by dividing these soft parts, the axillary artery should be compressed together with a portion of the skin of the armpit, between the fingers and thumb of an intelligent assistant. In this manner, hemorrhage may be prevented, even though the subclavian artery is not compressed. The rest of the operation consists in turning the edge of the knife inwards, cutting through the skin, vessels, etc., at the

inner side of the arm, and tying the brachial artery, and other vessels, requiring ligatures. The flaps are afterwards to be brought together.

PLATE A. 1. *b*.

Shews the first stage of the operation* at the shoulder-joint. It represents the patient sitting upright in a chair.

See pages 95 to 102.

* The flap is made and raised so as to expose the head of the humerus.

A. Plate 1. b.

A Plate 1.c

W. Cocks

PLATE A. 1 *c.*

This sketch represents the head of the humerus dislocated. The thumb of the surgeon is slipt into the capsule of the joint, and with the fingers of the same hand, on the outside of the integuments of the axilla, he grasps and compresses the axillary artery. By this he prepares to divide the remaining parts of the muscles and integuments.

---

(1). Place the patient upright* on a chair, put a sheet or table-cloth round the body; and, under the arm to be cut off, let the extremities of this cloth be held by a stout assistant. This is intended to support the patient when the assistant surgeon is pressing his thumb upon the artery, and without this precaution, the patient losing blood, and sinking under the pressure which it is necessary to make

* C. Bell's Operative Surgery.

above the clavicle, the pressure will be ineffectual, and the artery be left free.

(2). Let a stout assistant surgeon stand behind the patient; he is to place his thumb in the hollow above the clavicle, and to press the subclavian artery against the first rib. Let him reserve his most powerful exertion for the latter part of the operation.

(3). The surgeon takes the large amputating knife, and holding it like a sabre, he uses it much after the same fashion; with the left hand he grasps the mass of the deltoid muscle; he then cuts through the integuments and deltoid muscle near its insertion into the humerus, and changing the direction of the edge of the knife, he draws it so as to lift up the whole of the deltoid muscle, leaving it at its origin.

(4). The next part of the operation is to sink the scalpel into the cavity of the shoulder-joint, then the arm bone being drawn down by an assistant, room is given to introduce the fore finger of the left hand into the joint. The ligament is then cut from the glenoid cavity, the finger being the directory. Then, keeping the edge of the knife close to the neck of the humerus, the bone is separated from the soft parts, and the elbow being permitted to drop, the head of the bone rises free from the flesh of the arm.

(5). One motion of the knife cuts through the re-

maining flesh of the arm, and with it the artery and nerves.

(6). The artery is drawn out and tied.

(7). The muscular arteries are sought and secured with ligatures.

(8). Particular care is taken to see that the extremities of the nerves are lodged deep. The flap is let down so as to cover the lower part of the wound, and being secured by adhesive straps, the dressings are kept in their place by the spica bandage, which is a double-headed roller brought round from the opposite side of the body, and crossed over the shoulder.

Every one knows the difference of stopping the pulsation of the artery, and stopping the flow of blood through the artery. It is no security against hæmorrhage that the surgeon, feeling the wrist before proceeding to the operation, finds that the pressure of the assistant has stopt the pulse; notwithstanding this, blood flows from the vessels during the incisions, and velocity is necessary to success.

The dependance which the surgeon is obliged to have upon his assistant in the operation, must often render the operation impracticable.

In some cases the following method may be preferred:

1. Place the tape of the turniquet in the axilla, and the instrument itself on the top of the shoulder, and screw it tight: the artery is thus secured.

2. Make one decided cut with the large knife across the inner part of the arm. The mouth of the artery is seen gaping and quite distinct, and may be leisurely tied, free of the nerves.
3. Cut or loosen the tape of the turniquet, and make the flap by turning up the deltoid muscle.
4. Cut across the ligament, and separate the humerus, and secure the lesser arteries.

The advantage of this manner of operating would be the leisure and security in tying the great artery, without losing a drop of blood.

The appearance presented is in effect the same as when the operation is begun by forming the flap. Very often it must occur, that the place of the wound, or the destruction of integuments, will produce a necessity for varying the manner of making the flap in this amputation, and which, of course, must be left to the surgeon's judgment.

See pages 95 to 102.

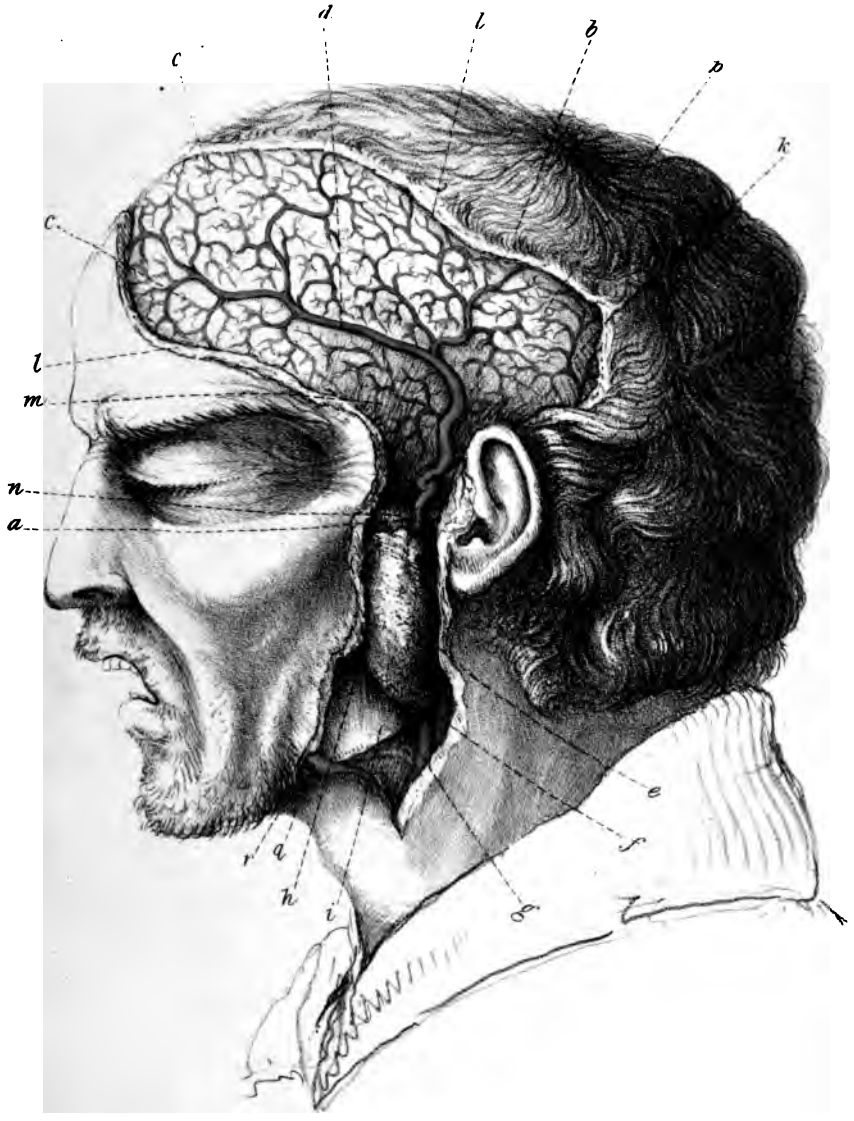

W P Cocks.

PLATE B. 6.

Surgical Anatomy of the Vessels of the Head.

The superficial temporal artery is a continuation of the external carotid, and is situated on the side of the head, immediately in front of the ear. It is at first lodged in the subcutaneous cellular tissue, between the superficial fascia and the subjacent plane of muscles.

The anterior branch of this artery anastomoses * with the frontal, while the posterior communicates with branches of the occipital. They often interosculate so as to form a complete net-work, which is always covered by the fascia superficialis and skin.

* In consequence of the numerous anastomoses, the surgeon is frequently obliged to tie or compress both extremities of the divided artery in order to arrest the hæmorrhage effectually; for if he obliterates but one of them, the blood will continue to flow from the other.

This plate represents the temporal artery* and its branches.

a. The temporal artery emerging from the parotid gland.
b. The parietal branch of the temporal artery.
c. Branches of the temporal inosculating with the frontal artery.
d. Frontal branch of the temporal artery.
e. Parotid gland.
f. Internal jugular vein.
g. Carotid artery.
h. Masseter muscle.
i. Angle of the lower jaw-bone.
k. Branches of the posterior temporal inosculating with the parietal branches.
l.l. Integuments.
m. Temporal muscle.
n. Zygoma.
o.p. Occipito-frontalis muscle.
q. Facial vein.
r. Facial artery.

* The temporal artery bifurcated unusually high in this subject.

See page 234.

W P Cocks

PLATE B. 6 a.

The mode of applying a ligature around the temporal artery.

a. Temporal artery* raised from its natural situation by means of a bent probe.
b. Temporal vein.
c. Integuments.
d. Silver probe with its broad end turned up.
e. Ligature of silk.

Operation of Bleeding in the Temporal Artery.—Where the artery appears near the surface, it may be done with the lancet, as in venesection, though the instrument in entering should here divide the vessel obliquely, going neither quite across it nor quite longitudinally. If the vessel be deep seated, the skin should be previously divided, so as to bring it into view, and then the opening be made with the lancet. Aneurisms are to be prevented after arteriotomy by a complete division of the vessel.

* Above the zygomatic arch, the superficial temporal artery is situated, about two or three lines in front of the auricle, at which place it would be very easy to open, or apply a ligature around it, if considered necessary.

PLATE B. 6 b.

Surgical Anatomy of the Vessels of the Lips.

a. Facial artery.*
b. Inferior coronary artery.†
c. Superior coronary artery.‡
d. Branches going to the side of the nose.
e. Levator labii superioris alæque nasi.
f. Continued trunk of the facial artery.
g. Twigs to the quadratus menti and skin.
h. Levator anguli oris.
i. Depressor anguli oris.

* If at any time we wish to compress this artery, and the edge of the masseter is not sufficiently evident through the skin, we should carry the finger forwards from the angle of the jaw, when we will soon meet with a superficial notch, in which the artery is always placed.

† In order to ascertain the exact course of this vessel, it is sufficient to imagine a curve passing about three lines from the edge of the lip, and terminating at the anterior and inferior part of the masseter.

‡ This vessel is placed three lines above the free border of the lip, in the posterior plane of the fleshy fibres, the direction of which it follows, and as the trunk of this artery is almost in immediate contact with the mucous membrane, we may readily feel its pulsations by applying the finger under the lip, and it is more easily wounded in this direction than from the surface.

WP Cocks.

k. Zygomaticus major.
l. Buccinator.
m. Jaw bone.
n. Integuments.
o. Masseter muscle.

The inferior coronary artery arises near the angle of the mouth, and, covered by the depressor of this part and the orbicular, proceeds towards the cavity of the mouth, in a winding and transverse direction, under the membrane of the mouth to its fellow of the opposite side, with which it inosculates.

The superior coronary artery is larger and more tortuous than the inferior, above which it arises, taking a similar course as it proceeds inwards across the upper lip. It passes under the zygomaticus and orbiculares, (plate B. 6 c.) and forms an arch by inosculation with the corresponding artery of the opposite side.

The arc of a circle, which the two superior coronaries united form, gives off an immense quantity of twigs, which descend or ascend parallel to each other, and terminate, for the most part, in the labial glands and mucous membrane. These are the twigs which constitute that beautiful and complex net-work observed in the latter when the lip is everted.

PLATE B. 6 c.

Surgical Anatomy of the Facial Artery and Vein.

a. Zygomaticus major.
b. Zygomaticus minor.
c. Buccinator.
d. Masseter.
**b.* Levator labii superioris alæque nasi.
k. Depressor anguli oris.
l. Parotid duct.*
1. Facial artery.
2. Superior coronary artery—(the dotted line extends beyond the artery, which is an error.)
3. Inferior coronary artery.
4. Transverse artery of the face.
5. Facial vein.
6. Middle facial nerve.

* The parotid duct, having emerged from the parotid gland, crosses the masseter, upon which it is immediately applied. It is covered by nerves, the largest of which run above it, and upon its superior margin also lies the transverse facial artery. It is situated eight or nine lines below the zygomatic arch, posteriorly, three or four only, anteriorly. Between it and this arch there is sometimes a distinct glandular lobule, which is the accessory of the parotid. The presence of this canal must make us very circumspect in forming our diagnosis, or prognosis of wounds or ulcers of this region, as well as in the performance of operations upon it.

Plate B6 c

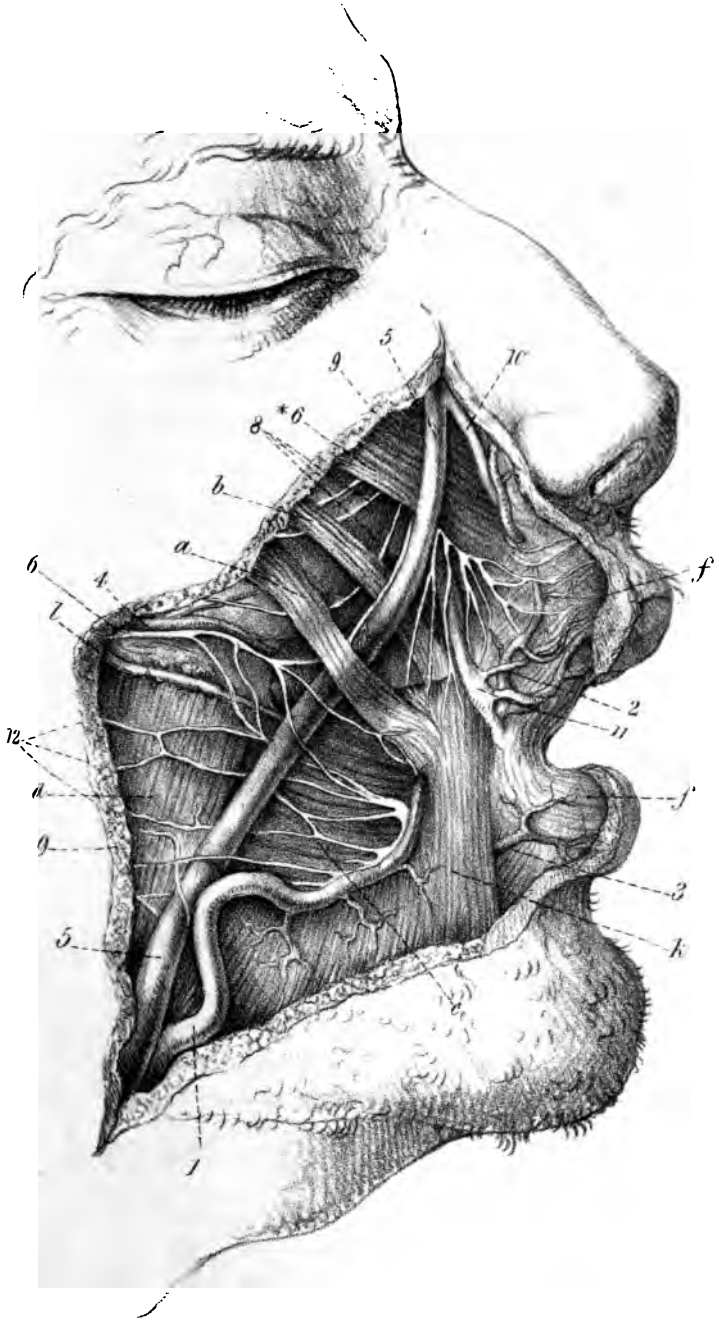

W. Cocks

7. Infra orbitar nerve.
8. Filiments of the facial nerve going to the side of the nose.
9. Integuments.
10. Nasal vein.
11. Labial vein.
12. Branches of the inferior facial nerve anastomosing with the buccal, and inferior branches of the middle facial nerve.

The facial, or external maxillary,* is the third branch that arises from the external carotid; it ascends by the side of the pharynx, and beneath the posterior head of the digastric and stylo-hyoideus muscles, to the submaxillary gland, between the lobes of which the artery runs, to the base of the inferior maxillary bone, over which, ascending on the face beneath the platisma myoides, and depressor anguli oris muscle, to the angle of the mouth, then under the zygomaticus major and zygomaticus minor muscles, resting on the buccinator muscle, along the upper lip, and ala of the nose, to the inner canthus of the eye, where it anastamoses with the nasal branch of the ophthalmic artery of the internal carotid.

* This artery may be easily found by dividing the space between the angle of the inferior maxillary bone and its symphysis into three proportional parts. The artery runs over the bone one-third from the angle and two from the symphysis.

The transverse artery of the face, rising under the zygoma from the parotid gland, it proceeds transversely to the face along with the salivary duct. In this course, if double, it gives branches to the parotid gland, the articulation of the maxilla, the masseter, the skin, the zygomaticus, and the orbicularis palpebrarum. It inosculates with the alveolar, palpebral, infra-orbital, and coronary arteries of the upper lip, and sometimes gives rise to the masseteric branches.

The facial vein* runs down obliquely from the inner canthus of the eye towards the angle of the lower jaw-bone; here uniting with the temporal vein, it forms the external jugular vein.

* Opening the facial vein, in cases of diseases of the eyes and brain, would be attended with very beneficial results. The opening must not be made at the lower part of the face, on account of the proximity of the artery.

Plate B 6 d.

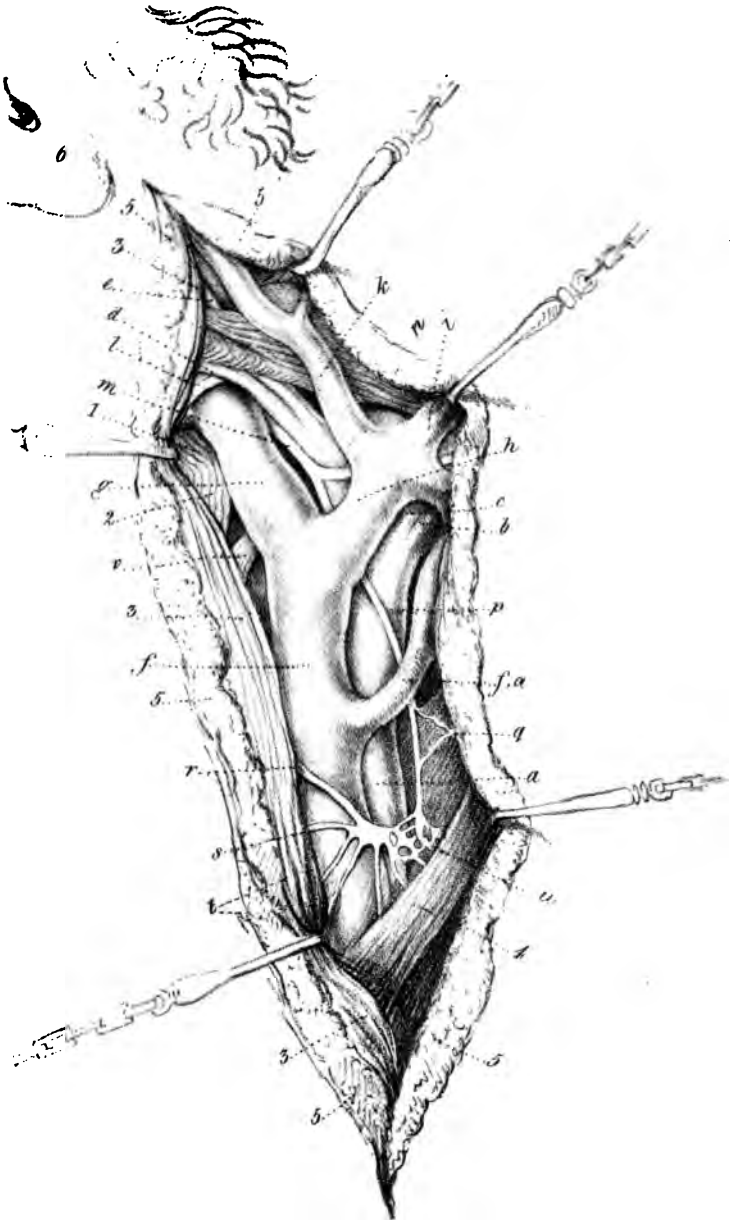

W^P Cocks

PLATE B. 6 d.

Surgical Anatomy of the Vessels of the Neck.

a. Carotid artery.
b. Superior thyroid artery.*
c. External maxillary or facial.

* The superior thyroid artery arises from the anterior part of the external carotid, and descends in a winding direction downwards and inwards to the superior margin of the thyroid gland.

Operation.—The trunk of the superior thyroid artery may be readily exposed and tied, either in the direction of a line drawn from the cornu of the os hyoides to the anterior and inferior part of the thyroid cartilage, or by making an incision obliquely downwards and outwards, from the os hyoides to the sterno-mastoid muscle; or, lastly, by dividing the parts in the omo-hyoid triangle parallel to the sterno mastoid muscle. In this space, in fact, the artery, before it reaches the gland, is covered only by the ramus descendens noni, some veins, the aponeurosis, and the common integuments.

Operation of tying the inferior thyroid artery.—The integuments must be divided along the anterior edge of the sterno-cleido-mastoid muscle; and push to one side the cellulo-aponeurotic sheath which encloses the carotid; we then seek for the inferior thyroid artery, a little under and behind the omo-hyoid muscle. In applying the ligature, the two principal nerves which pass before and behind the vessel must not be included; consequently, we must vary the method according to the position of the parts. If the nervous trunks are very close to the trachea,

d. Occipital.*
e. Internal maxillary.†
f. Internal jugular vein.‡

the needle must be passed from below upwards, and from within outwards; if these nerves are nearer the carotid, we should pass it in the opposite direction.

* It arises from the posterior part of the external carotid, under the parotid gland, and opposite the lingual artery. It ascends, at first, obliquely backwards, beneath the sterno-cleido-mastoideus muscle along the posterior belly of the digastricus muscle and the hypo-glossal nerve. It then passes horizontally between the transverse process of the atlas and the mastoid process, after crossing the direction of the internal jugular vein and pneumo-gastric nerve, above which it is situated. It then bends back upon the occipital bone, covered by the splenius muscle, under the inner edge of which it emerges to become sub-cutaneous, and ascends in a tortuous manner upon the back part of the head, where it terminates.

† This artery is larger than the temporal. It arises above the lateral ligament of the maxilla, about the middle of the ramus of the inferior maxillary bone, before the external pterygoid, and bending inwards, forwards, and downwards, is concealed under the maxilla. It then rises obliquely upwards and forwards to the space lying between the tuber maxillare and the pterygoid process, and, as it proceeds in a tortuous manner, it is lost here in three or four branches, or rather in the spheno-maxillary fissure.

‡ The internal, or deep-seated jugular vein, is of considerable size, and deeply seated in its entire course. It commences in the jugular fossa, being part of the foramen lacerum posterius, where it is continuous with the lateral sinus of the brain. Placed at first close to the internal carotid artery, it subsequently lies parallel with, and to the outside of, the common carotid, as far as the sternal end of the clavicle, where it joins at an angle with the

f.a. Pharyngeal vein.
g. Cerebral internal jugular vein.
h. Superficial trunk of the internal jugular vein.
i. Facial vein.
k. Temporal vein.
l. Spinal accessory nerve.*
m. Great hypoglossal nerve.†

subclavian vein, and so forms the vena innominata. The internal jugular vein receives the blood from the sinuses of the dura mater, the ophthalmic, facial, laryngeal, and pharyngeal veins. The left jugular vein lies on a plane anterior to that of the right side, and somewhat overlaps the left carotid artery, in order to join the left vena innominata, which crosses the upper orifice of the thorax anterior to the three great arteries emerging from that cavity; whereas the jugular vein of the right side inclines outwards and backwards, to meet the right subclavian vein; the confluence of these forming the right vena innominata, which vein descends almost perpendicularly into the cavity of the chest.

* From the medulla oblongata and superior part of the medulla spinalis. It passes through the occipital hole into the cranium, and accompanies the par vagum through the foramen lacerum posticum; it then separates from the eighth pair, and passes towards the shoulder, giving branches to the pharynx and muscles on the back part of the neck, and communicating with the lingual, sub-occipital, and superior cervical nerves.

† From the corpus pyramidale and olivare of each side; passes through the condyloid foramen; goes between the carotid artery and jugular vein to the muscles of the tongue, and anastomoses with the par vagum, spinal accessory, and superior cervical nerves. It gives off, in its course, the descendens noni, which passes along with the carotid, gives branches to the muscles of the neck and trachea, and anastomoses with the three superior cervicals.

n. Trunk of the hypoglossal nerve.
o. Descendens noni.
p. Course of the descendens noni.
q. Branches from the descendens noni.
r. Nerves from the second cervical joining the descendens noni.
s. A nerve from the third cervical joining the descendens noni.
t. Nervous filiments from the fourth and fifth cervical nerves joining the plexus of the descendens.
u. A nervous plexus formed by the anastomosing branches, of the second and third cervical nerves, with the descendens noni.
v. Second cervical nerve.
1. Obliquus capitis superior.
2. The superior attachment of the levator scapulæ muscle.
3. Mastoid muscle forcibly pulled to the posterior region of the neck.
4. Omo-hyoideus muscle.
5. Integuments.
6. The ear.

PLATE B. 6 e.

Anatomy of the Carotid Artery.

The common carotid ascends obliquely upwards and outwards, its direction coinciding with that of a line drawn from the sterno-clavicular articulation to midway between the angle of the jaw and mastoid process.* Opposite the upper border of the thyroid cartilage, the vessel divides into two trunks, called external and internal carotid.

* By laying a thread from the anterior part of the mastoid process to the centre of the upper bone of the sternum, and by extending another from the side of the body of the os hyoides to a little nearer the sternum than the central part of the clavicle, we describe pretty accurately the course of the muscles. The first thread defines the anterior margin of the sterno-mastoid, while the other follows the direction of the omo-hyoideus; just beneath the point of intersection of these two lines the common carotid is generally placed. Above this spot the course of the artery may be discovered, by laying a thread from the point of decussation up to the jaw-bone.

The internal* passes through the foramen carotideum of the temporal bone, and distributes its branches to the brain and eye; the other sends its ramifications to the external part of the head and face.

The right carotid is shorter nearer the median line, more anterior and thicker than the left, which is owing to its being given off by the brachio-cephalic trunk. This disposition affords an additional reason for not performing œsophogotomy on this side, for not applying a ligature upon the artery too near the inferior part of the neck, and for taking suitable precautions in the operation of tracheotomy. Anteriorly, the left carotid is, in the first place, separated from the sternal portion of the sterno-mastoid muscle by a space of about an inch in extent, which is filled with cellular tissue, fat, veins of considerable size, some descending branches of the cervical plexus, &c. On the right, this interval is less extensive, and the artery runs nearer the anterior margin of the muscle.

The external carotid mounts vertically under the platisma, passes beneath the hypo-glossal

* The internal carotid is generally situated about eight or ten lines behind and external to the tonsils, so that in plunging the bistoury between the pillars of the velum palati, it would be easier to strike this vessel when the tonsil is in a state of tumefaction, as it is then carried near to the artery.

nerve, and the posterior belly of the digastric and the stylo-hyoid muscles, and runs a little outwards and backwards, and sinks under the parotid gland. In this course it gives off, anteriorly, the superior thyroid arteries, the facial, and the lingual; posteriorly, the occipital and auricular; and internally, the inferior pharyngeal.

PLATE B. 6 e.

---

*Operation of Tying the Carotid Artery.**

a. Omo-hyoid muscle.
b. Sheath of the carotid artery.
c. Artery exposed.
d. Mastoid muscle.
e. Sterno-thyroideus muscle.

* There are two situations in the neck in which the carotid artery may be exposed and tied, either above or below the omo-hyoid muscle.

The operation above the muscle is performed as follows:—the chin being turned to the opposite side, and pushed upwards, so as to extend the parts, an incision, three inches in length, may be made along the inner border of the sterno-mastoideus, beginning below the angle of the jaw, and continued down in the interval between the muscle just named and the side of the larynx. The skin being divided, the platisma is to be cut through to the same extent, and afterwards the cervical fascia, in doing which a portion of the membrane should be pinched up by the forceps, and cut across, so as to make a small opening for the introduction of a director, on which it is to be slit up.

This will expose the sheath of the vessels, which is next to be opened by raising a small portion of it over the artery with a pair of forceps, and dividing it by cautious touches of the knife held in a horizontal direction. (The sheath which the aponeurosis gives to the artery, the opening of which is one of the most delicate

Plate B 6.e.

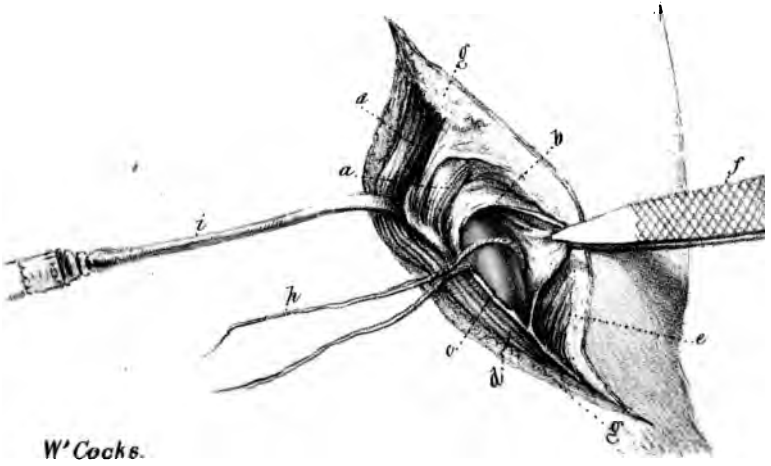

W' Cocks.

f. A pair of forceps extending a portion of the cut sheath.

g. Integuments.

steps of the operation; for if we cut too much outwards, the internal jugular vein may be wounded; if we incise directly upon the artery, we might open the vessel itself. Nevertheless, if this sheath is not divided, we almost inevitably include in the ligature, together with the carotid, both the descendens noni and cardiac nerves, which are more or less adherent to its outer surface.) This opening being enlarged, the internal jugular vein will appear distending itself occasionally, so as nearly to conceal the artery. When the sheath has been freely opened, the handle of a scalpel is to be insinuated between the artery and jugular vein, retaining it as closely as possible in contact with the former. By pressing it gently but steadily forward, and by moving it slightly upward and downward while the vein is flaccid, and desisting while it is tense, the artery will soon be detached from its connexion with the neighbouring parts on that side. By similar means it is to be separated from its adhesions on the tracheal side. When about half an inch of the artery is completely insulated, an assistant must gently press the vein and par vagum towards the mastoid muscle, and an aneurismal blunt needle, armed with a small, firm, and round double ligature, may be passed round the artery, taking care to direct it from without inwards, and to keep the end of the instrument close to the vessel, so as to avoid the sympathetic nerve and some of its cardiac branches, particularly the superficialis cordis, which lies internal to the artery and close to the sheath.

The ligature being tied, one end of it may be cut off, and the other placed between the edges of the wound, opposite its attachment to the artery, the lips of the wound are to be brought in opposition by means of adhesive plaster. The patient should lie with his head well supported.

Below the muscle, the incision through the integuments should

h. Ligature passed round the artery.
i. Blunt hook with which the mastoid muscle is held aside.

commence on a level with the cricoid cartilage, and extend for fully three inches, down towards the sterno-clavicular articulation. The skin, platisma, and fascia, being successively divided, the head must be slightly elevated, in order to relax the muscles, and allow of their being drawn aside so as to bring the sheath of the vessels into view. When this is effected, the subsequent steps are the same as in the operation above the muscle.

If we tie the artery in the omo-hyoidean triangle, we must depress the omo-hyoideus muscle inward; and when in the omo-trachael angle, it must be pulled upwards and outward, in this manner we may generally dispense with cutting this small muscle across.

External Carotid.—Cut through the skin from the lobe of the ear towards the point of the os hyoides; dissect through the platisma myoides, you will then come to the digastric muscle; dissect a little along its upper edge, and there you will find the stylo-hyoideus muscle; upon the forcing this last muscle a little downward, you will discover the continued trunk of the external carotid artery.

BANDAGES.

The use of bandages is to keep dressings, compresses, splints, &c. in their proper situations; to compress blood-vessels, so as to restrain hemorrhage; to rectify certain deformities, by holding the deranged parts in a natural position, or inclining them towards it; and to unite parts, in which there is a solution of continuity. Bandages are either simple or compound; they are also sometimes divided into general and particular. The latter often derive their names from the parts to which they are usually applied.

See page 221.

PLATE D. 1.

Bandages for the Head.

Fig. 1.

Shews the triangular, or simple kerchief for the head, (couvre chef en triangle.)

a.a.a. The parts of it which invest the forehead, vertex, and part of the occiput.

b. Its corners tied upon the occiput.

Fig. 2.

Represents the manner in which the grand kerchief or six-angled bandage is applied.

a.a.a. Its middle corners tied under the chin.

b. One of its anterior corners, which, with its fellow, is carried round the occiput, and fastened on each side near the ears.

c.c. The posterior angles brought from the occiput to the forehead, and there fastened by the knob, *d.*

e.e. The middle of the bandage investing the head.

See pages 221 to 225.

Fig 1. *Plate* D.1.

Fig 2.

W P Cooke.

Fig 1. *Plate* D. 2.

Fig. 2

WP Cocks.

PLATE D. 2.

The Uniting Bandage.

Fig. 1.

Demonstrates the uniting bandage of the forehead.

a. The longitudinal wound.

b. The slit in the bandage upon the wound, through which its other part *c.* is passed.

d d. The two heads of the bandage, by drawing which the lips of the wounds are approximated, and then they terminate circularly about the head.

See pages 221 to 225.

Fig. 2.

Represents the uniting bandage applied to a longitudinal wound near the top of the head.

See pages 221 to 225.

Plate D3.

Fig 1.

Fig 2.

W^P Cocks.

PLATE D. 3.

Bandages for Arteriotomy in the Temple.

Fig. 1.

a.b. The first round made by the two roller-heads, the middle of which being applied upon the sound temple, is brought round in the direction *a.b.* and crossed upon the compress on the divided artery *c.*, so as to form a knot or protuberance; after which they pass round the head in the opposite course *d.e.* under the chin, and over the top to the sound temple, where they cross again as before at *c.*

See pages 221 to 225.

Fig. 2.

The circular bandage for arteriotomy.

a.b. The first circle, made by the roller-heads, the middle of which being applied upon the sound temple, is brought round in the direction *a. b.* and crossed upon the compress on the divided artery *c.*, so as to form a knot or protuberance, over which two or more turns of the roller are to be applied with a moderate degree of pressure.

Plate D 4.

Fig 1

Fig 2.

Fig 3

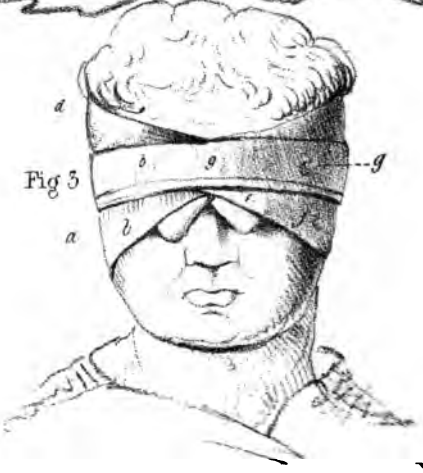

W.P. Cocks.

PLATE D. 4.

Represents Bandages for the Eyes.

Fig. 1.

Bandage (monoculus) for the binding up of one eye.

a.a. Denote the first round which passes from the occiput round the ear and cheek, over the left eye, and then over the forehead *b.* to its beginning at the occiput.

c.c.c. The circles about the temples, where the bandage terminates.

Fig. 2.

The monoculus, formed of a handkerchief rolled up, and tied obliquely about the head.

Fig. 3.

The binoculus for investing both eyes, applied by bringing the bandage from the forehead to the occiput, in the direction *a.b.c.*, over the left eye and crossing on the occiput; it then covers the right eye, in the course *d.e.f.*, returning to the occiput, and is finally spent in the circular turns *g.g.g.* over both eyes.

Fig 1. H. *Plate*

Fig 2.

PLATE 3. H.

CANCER OF THE NOSE AND LIP,

With exfoliation of the Bones of the Nose and Upper Jaw.

Fig. 1.

A complete destruction of the integuments and bones of the nose, and of the lateral and superior portions of the bones of the orbits, with loss of sight from cancer.

When this sketch was taken, the frontal bone was thickened, spongy, and looked very black; its superior edge was separated from the parietal bones, and projected forward on the top of the face, its inferior, or orbital extremity, was firmly adherent to the integuments of the forehead, and would allow of slight motion. The dura mater, covering the denuded portion of brain, was much thickened and very opaque. The motion of the brain was quite evident.

Fig. 2.

In this case, the cancer was situated in the upper lip, and, for want of timely excision, the integuments of the cheek, with the bones of the nose and upper jaw and palate, were completely destroyed.

See pages 284, 287.

DISLOCATIONS IN GENERAL.

'islocation takes place every time that the articular extremities of bones abandon their natural relations. Whether it be that the head of a bone escapes from a cavity destined to receive it, or that the surfaces of the joint cease to correspond one to the other. The dislocation may be either total or partial. Hence dislocations are divided into complete and incomplete.

islocations, taken in a general point of view, differ from one another, with respect to the articulation in which they take place; the extent of the dislocation; the direction in which the bone is displaced; the length of time they have continued; the circumstances which accompany them; and which mark them out as simple or compound; and the cause that has produced them.

'ery dislocation produces pain and incapacity in the limb; but these are only equivocal symptoms, and cannot distinguish the case from a

fracture, nor even from a simple contusion. Our diagnosis ought to be founded on the existence of symptoms manifest to the senses, such as an elongation or shortening of the limb, a change in its shape and direction, and an absolute impossibility of performing certain motions.

Fig 1.

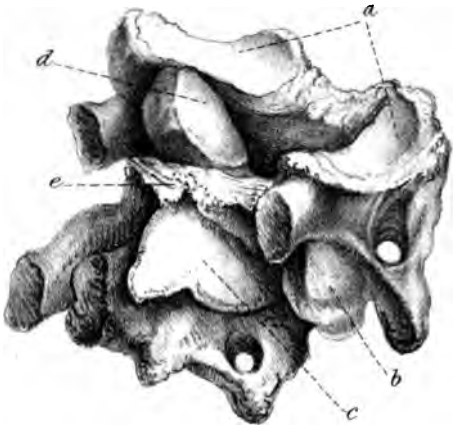

Fig 2.

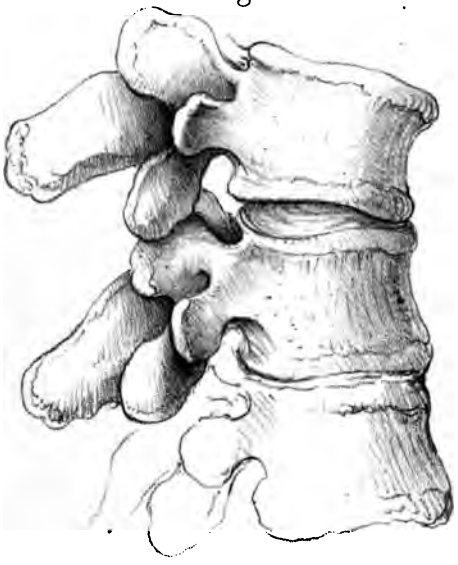

W.P. Cocks.

PLATE K. 1.

This plate represents dislocations of the vertebra.

Fig. 1.

Dislocation of the Atlas.

a. The condyloid cavities of the atlas.
b. The lower articulating process of the atlas, separated from the corresponding process of the dentata.
c. Surface of the tooth-like process, which should correspond with the articulating process (*b*).
d. The tooth-like process of the vertebra, which has started in consequence of softening and rupture of the transverse ligament.
e. A portion of the ligament remaining, against which the process *d.* rests.

Dislocation of the head from the atlas, from a diseased state of the ligaments.—Pain in the neck, becoming more severe at night, or in

the swallowing a large mouthful, or drawing a deep breath, is the first symptom. Pain on one side of the neck, especially when the head is moved towards the shoulder, it extends from the larynx towards the nape, and often to the scapula of the pained side; pressure on the region of the first and second vertebræ produces considerable pain, and thus points out the seat of the disease. The head sinks towards one shoulder, the face being turned a little down. If both sides are affected, the the head will incline directly forwards. The patient feels as if the head were too heavy, and he moves from the sitting to the lying position, or *vice versâ*. A peculiar expression of pain in the countenance.

In these cases, nothing can be more obvious than that there must be a destruction, or, at all events, a thoroughly diseased state of the ligaments between the atlas and dentatus, and those connecting the dental process to the occiput.

See pages 390 to 393.

First cervical from the second.—When the rotatory motion of the head is forced beyond its proper limits, the ligaments which tie the processus dentatus to the edge of the foramen magnum are torn; and supposing the head to be forced from the left to the right, the left side of the body of the vertebra is carried before its corresponding articulating surface, while the right side falls behind its corresponding surface.

Sometimes the tooth-like process, the ligaments of which are broken, leaves the ring formed for it by the transverse ligament, and the anterior arch of the first vertebra, and presses on the spinal marrow.*

The symptoms produced by pressure on the spinal marrow, are a loss of sensibility and of motion in the parts supplied from that portion of the medulla spinalis, below the accident.†

* Lesion of the spinal marrow at this point is quickly fatal.

† If the upper vertebræ be injured, sensation is lost in the upper extremities; if the dorsal vertebræ, or upper lumbar, the lower extremities become insensible; and if the lumbar be injured, the fœces pass involuntarily, and the urine is retained.

Fig. 2.

Plan of Dislocated Vertebræ.

The articulating process of the upper and lower vertebræ should lie flat on each other, instead of which their points stand opposed, so that their bodies cannot come into their regular approximation, but stand with oblique surfaces.

See pages 390 to 393.

Fig 2.

Fig 1.

Fig 3.

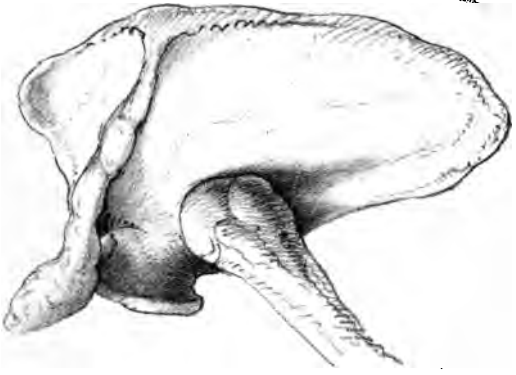

W. Cocks.

PLATE K. 2.

These sketches represent dislocations of the os humeri.

Fig. 1.

Dislocation of the os humeri in the axilla.

Fig. 2.

Dislocation of the os humeri forwards, under the clavicle, and below the pectoral muscle.

Fig. 3.

Dislocation backwards, on the dorsum of the scapula, below the spine.

In the axilla, the arm is longer than the other, it loses its vertical position, and inclines obliquely downwards and outwards, and the elbow is very much separated from the body if the dislocation be recent.

When in the healthy state, if the fingers are moved along the external part of the os humeri, an equal resistance is felt along its whole length; but if in a case of dislocation, it is only at the middle part that this resistance is felt; on the upper part, the integuments, no longer supported by the superior extremity of the bone, yield to the pressure of the fingers. The acromion process projects; an empty space is felt under it, in which the head of the humerus should be placed; the summit of the shoulder has lost its roundness; and a hard tumour, formed by the head of the humerus, is found in the axilla. The motions of the joint are, in a great degree, destroyed, especially upwards and outwards, and the patient cannot raise his arm by muscular effort.

See pages 394 to 401.

The second dislocation is forwards, beneath the clavicle, upon the second rib, and having the coracoid process on its outer side.

This accident may be known from the preceding, by the projection of the acromion appearing greater—from the depression of the deltoid being more considerable—by there being less pain, and by there being a prominence beneath the middle of the clavicle. On rotating the arm, the head of the bone may be felt to roll, the elbow is thrown from the side, and at the same time backwards, and the motions of the arm are more confined than in the first dislocation.

Dislocation backwards on the dorsum of the scapula.

In this case the head of the os humeri is thrown upon the dorsum of the scapula, below the spine, where it forms a projection, and this enlargement may be seen and felt to move when the elbow is rotated. The motions of the arm are less confined than in either of the former dislocations.

See pages 394 to 401.

PLATE K. 2 a.

Dislocations of the os humeri.

The mode of reducing dislocations of the os humeri by the heel in the axilla.

The head of the humerus may be displaced from the glenoid cavity of the scapula in four directions; three of the dislocations are complete, and one not perfectly so.

The first is downwards and inwards into the axilla.

The second is forwards, under the pectoral muscle, below the clavicle.

The third is backwards on the dorsum of the scapula, below the spine.

The fourth is only partial when the head of the bone rests against the external side of the coracoid process of the scapula.

See pages 397, 398, 399.

The shoulder-joint, which is very liable to luxations in a general sense, is not equally so at all points. There are some where a dislocation cannot occur; there are others where, though possible, such an accident has never been observed.

Plate K. 2.b.

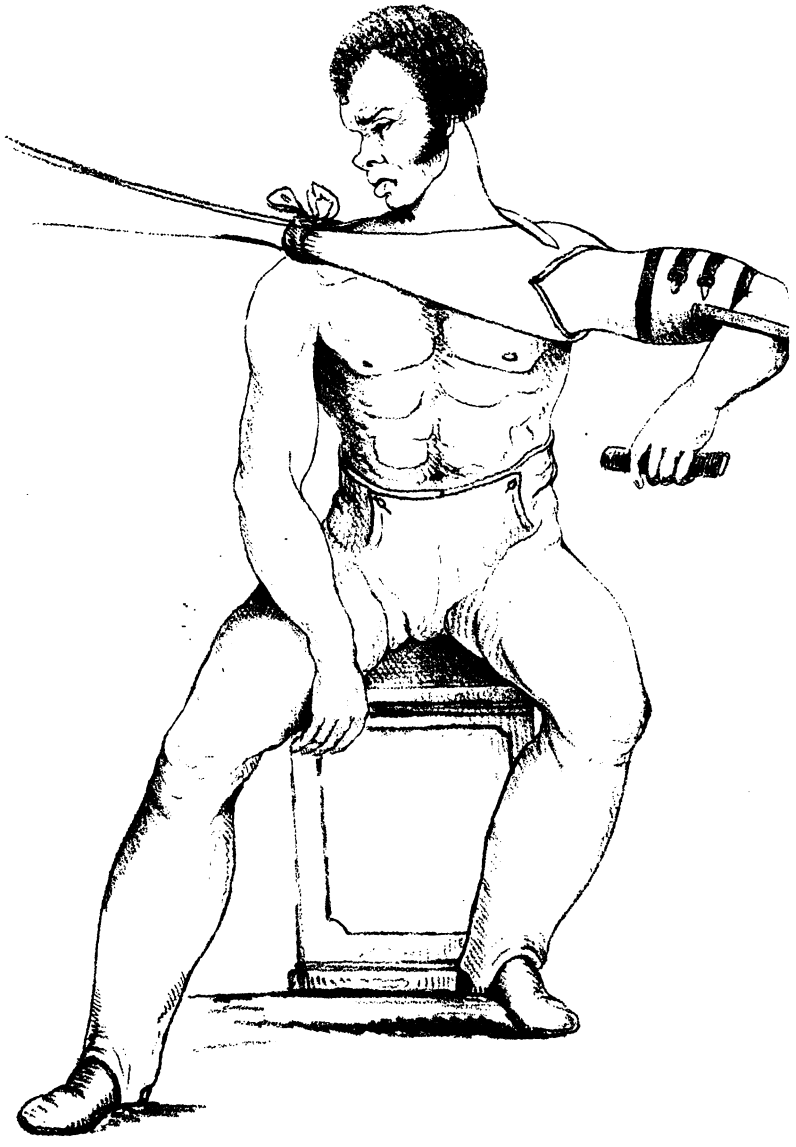

W.P. Cockl

PLATE K. 2 b.

Mode of reducing by the pulley; shewing the manner in which the scapula is fixed by a bandage, which receives the arm, and the pulleys applied above the elbow; as well as the direction in which extension is to be made in dislocation in the axilla. If the dislocation be forwards under the clavicle, the arm must be somewhat lowered to avoid the coracoid process.

See page 399.

PLATE K. 2 c.

The mode of reducing the dislocation downwards, by the knee in the axilla.

See page 398.

Plate K. 2.c.

PLATE K. 2 c.

The mode of reducing the dislocation downwards, by the knee in the axilla.

See page 398.

Plate K. 2.c.

PLATE K. 3.

This sketch represents a dislocation of the ulna backwards.

a. Os humeri.
b. Olecranon process thrown behind the condyles of the os humeri.
c. Ulna.
d. Radius.

The elbow-joint may be dislocated in five different ways.

1st. The ulna and radius backwards.*

* In the antero-posterior direction, the inferior extremity of the humerus presents a kind of cylinder, received into a cavity of the same form, belonging to the ulna.

The dislocation of the fore-arm forwards is impossible, on account of the extension and anterior curvature of the olecranon, which embraces the posterior part of the articular pulley of the humerus; and in order that the dislocation backwards should take place, the top of the coronoid process must be carried beyond the vertical diameter of this articular pulley; for the obliquity of these surfaces is such, that, without it, this last eminence would

2d. The ulna and radius laterally.*
3d. The ulna separately from the radius.†
4th. The radius alone forwards.
5th. The radius alone backwards.

fall again to the bottom of the great sigmoid cavity, as soon as the power which produces the displacement ceased to act; it is also on account of the convexity of this articular pulley that the coronoid process glides into the cavity destined for the olecranon, when it has gone beyond the point spoken of. The anterior and posterior ligaments of the articulation do not so much oppose the dislocation of the fore-arm backwards, as the circumstances related, and the situation of the muscles which surround the articulation.

* The internal lateral ligament, which passes from the outer condyle to the olecranon and coronoid process of the ulna, and external lateral ligament, which is fixed to the external tuberosity of the humerus, and terminates in the annular ligament of the radius, increases the strength of the elbow-joint, and renders the lateral dislocation of the fore-arm very difficult.

† In infants, the annular ligament, which only belongs to the superior radio-ulnar articulation, is generally less resisting than in the adult; it is the same in the tendinous fibres of the extensors, which contribute very much to increase the strength of the articulation. Hence, the dislocation of the head of the radius on the ulna is more frequent in young subjects than at a more advanced age; but what contributes still more to increase the facility with which this kind of dislocation takes place, is the proportionably smaller extent of the articular cavity at the external surface of the radius, as well as the greater length of the annular ligament, which is, consequently, more capable of extension, and also more disposed to give way.

In the first case—The ulna and radius form a considerable projection above the natural position of the olecranon posteriorly, with a depression on each side; on the fore part, the extremity of the humerus occasions a swelling, behind the tendon of the biceps muscle. The flexon of the joint is almost destroyed, and the fore-arm and hand are fixed in a supine position.

In the 2nd case—In the external displacement, the olecranon forms a greater projection than in the dislocation backwards, as its coronoid process is seated upon the external condyle of the humerus, instead of being placed in its posterior fossa; the head of the radius is thrown to the outer side, and behind, where it forms a swelling, which moves when the hand is rotated.

Internally the olecranon projects equally as in the former case, but the head of the radius falls into the posterior fossa of the humerus; the external condyle forms a large protuberance on the outer side.

In the 3rd case—The prominence of the olecranon behind the joint, and the fore-arm and hand being twisted inwards, accompanied with a painful rigidity of the arm, sufficiently distinguishes the nature of the accident.

In the 4th case—The fore-arm is a little bent, but cannot be either completely flexed or ex-

tended. When an attempt is made to bend the fore-arm, the motion is suddenly stopped by the striking of the radius against the humerus. The hand is nearly in a state of complete pronation, but cannot be rendered entirely so, nor can it be placed in a supine position.

The head of the radius may be felt on the fore and upper part of the elbow-joint, and its movements are perceptible when the hand is rotated.

In the 5th case—The head of the radius was thrown behind, and to the outside of the external condyle of the humerus, when it formed a projection which could be readily seen, as well as felt, when the arm was extended. The oblique and coronary ligaments were torn through, and the capsular ligament was partially lacerated.

See pages 401 to 405.

Fig. 3.

Compound dislocation of the thumb.

Fig. 4.

Compound dislocation of the first phalanx of the thumb.

a. Metacarpal bone.
b. First phalanx thrown backwards.
c. Second phalanx.
d. First phalanx dislocated.
e. Tendon of the flexor longus pollicis torn through.

Fig. 5.

Mode of reduction of the thumb.

See page 386.

Plate K 6.

W. Cocks.

PLATE K. 6.

The Mode of Reducing a Dislocation of the Lower Jaw-bone.

The patient being seated on a chair, the head fixed against the breast of an assistant, the surgeon covers his thumbs with linen, and places them as far back as possible on the last great molar teeth, whilst he embraces the jaw with the other four fingers bent upon the chin. He depresses the bone by pressing on the great molares with his thumbs; he carries it backwards to disengage the condyles, and raises the chin with the last fingers; he immediately glides the thumbs between the dentar arches and the cheeks, to avoid being bit by the sudden and violent action with which the elevators of the jaw make the condyles re-enter the glenoid cavities.

The parts are to be retained in their natural situation by means of the sling or chin-cloth; and support the patient for some days with liquid aliments.

In cases of partial dislocation, the jaw may be reduced by means of the cork or lever of wood.

The corks generally employed are those used for stopping the common quart bottles. They should be placed one on each side of the mouth, behind the molares teeth, after which the chin is to be raised in the manner already described. A long piece of wood is sometimes employed in these cases as a lever, introducing it between the molares, first on one side, then upon the other, and each time raising the extremity of the wood furthest from the mouth, so as to depress that part of the lower jaw beyond the molar teeth, and with it the condyloid process, when the action of the muscle will draw it into its articular cavity.

See pages 389, 390.

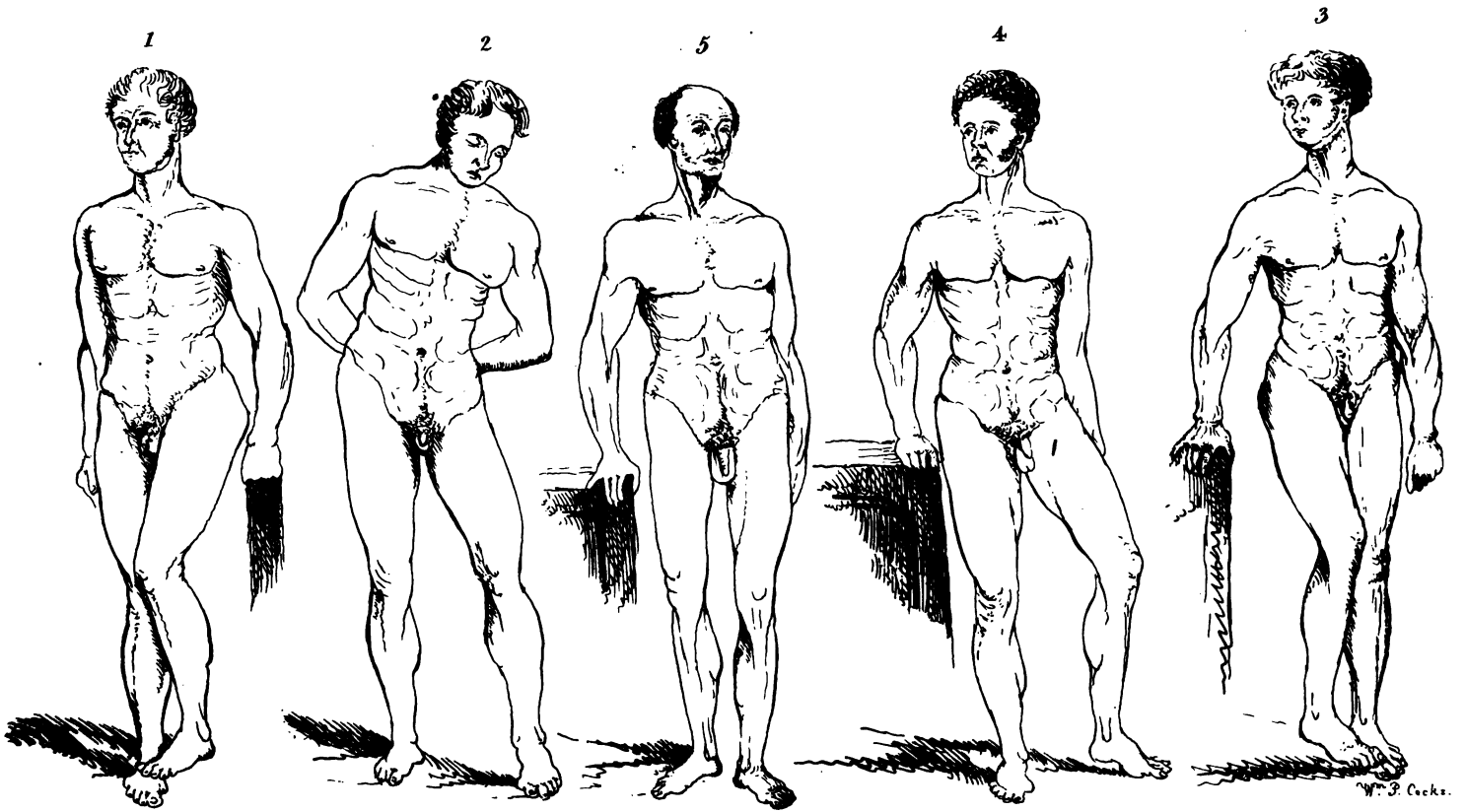
1
2
5
4
3
Wm. J. Cocks.

PLATE K. 8.

Shewing the positions of the limb in the different dislocations of the hip and fracture of the neck of the thigh-bone.

Fig. 1.

The dislocation upwards upon the dorsum ilii.* The limb shortened—the hip projecting—the knee and foot turned inwards, with the toes resting over the metatarsus of the sound limb.

Fig. 2.

The dislocation downwards into the foramen ovale.† The limb lengthened—the knee advanced and separated from the other—the toes pointed—the heel does not touch the ground—the body bent forward.

Fig. 3.

The dislocation into the ischiatic notch.‡ The limb shortened—the knee and foot a little turned inwards, with the great toe resting against the ball of the great toe of the sound limb.

* See page 408. † Page 410. ‡ Page 411.

Fig. 4.

The dislocation on the pubes.* Projection at Poupart's ligament from the head of the bone, the limb widely separated from the other, and the knee and foot turned outwards—the limb a little shortened.

Fig. 5.

Fracture of the neck of the thigh-bone.† The leg shorter—the knee turned out—the patella from one to two inches above the other, and sometimes more—the foot is generally everted, and does not reach the ground when the other leg is straight—the leg is easily drawn to the same length with the other, and then, if rotated, a crepitus is felt.

* See page 411. † See page 516.

Fig. 1.

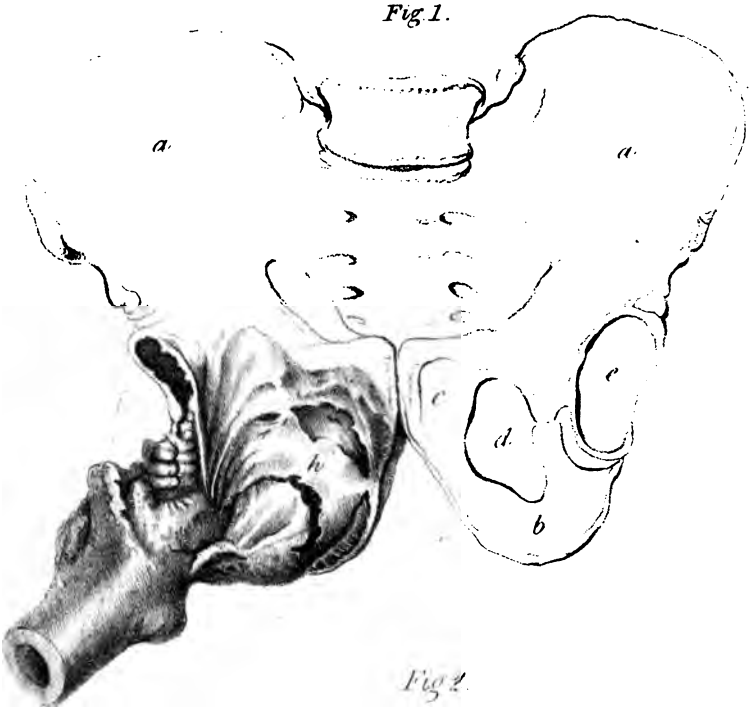

Fig. 2.

PLATE K. 8 a.

Fig. 1

Shows a dislocation into the foramen ovale* which had never been reduced, and beautifully exhibits the resources of nature, in forming a new socket for the head of the bone, and allowing of the restoration of a considerable degree of motion.

a. Right and left ilium.

b. Ischium.

c. Pubes.

d. Foramen ovale.

e. Left acetabulum.

f. Sacrum.

g. Os femoris.

h. The new acetabulum, formed in the foramen ovale, in which the head of the thigh-bone was contained, and in which it was so completely enclosed, that it became impossible to remove it, unless a portion of the new socket were broken away. It was lined by a ligamentous substance, on which the head of the bone moved to a considerable extent.

i. The original acetabulum, situated above the level, and to the outer side of the new cavity.

* Vide page 410.

Dislocation in the Ischiatic Notch.†

Fig. 2.

a. A portion of the ligamentum teres.

b. A new capsular ligament formed around the head of the bone, and composed of cellular membrane condensed by inflammation.

c. Ilium.

d. The head of the os femoris thrown into the ischiatic notch, and situated between the posterior and inferior spinous process of the ilium, and the spinous process of the ischium.

† Vide page 410, 411.

Plate K 8.a.

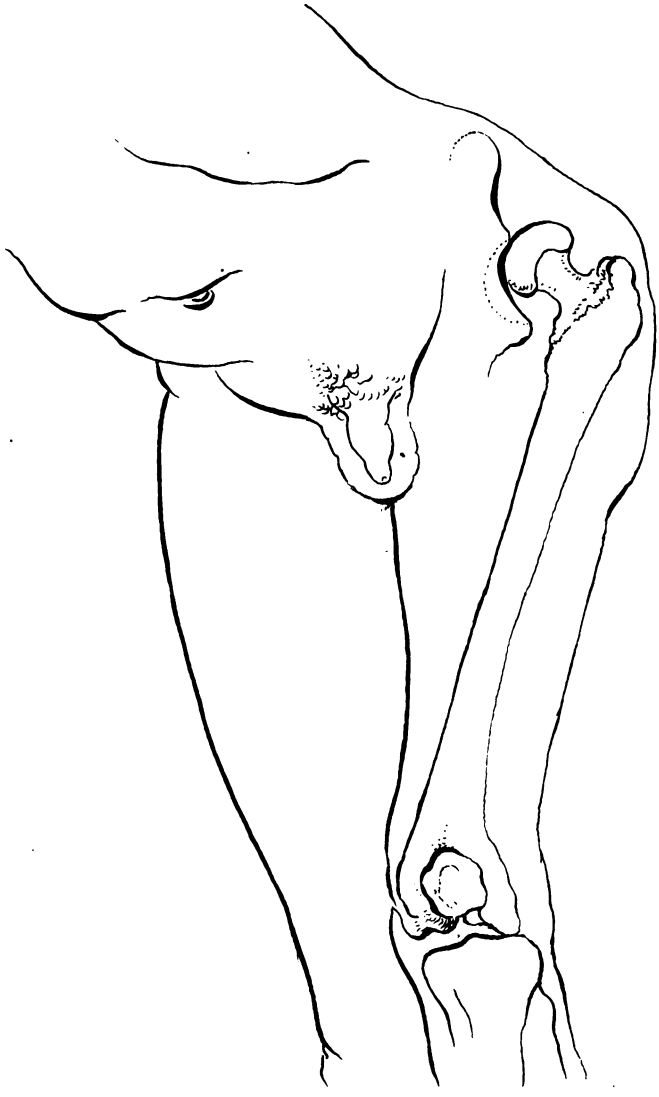

W. Cocks.

PLATE K. 8 b.

Consecutive Dislocation of the Hip-joint.

Whenever there is the slightest degree of inflammation of the hip-joint, whether it proceeds from an injury, or be a spontaneous and constitutional inflammation, there is an inclination of the pelvis on the head of the thigh-bone, and the inclination of the trunk from the line of the thigh-bone increases in proportion to the degree of inflammation. At last the disease continuing, the affected leg and trunk will form an angle of 45°, and the head of the femur will be thus raised upon the lip of the acetabulum and prepared to start out of the socket altogether.

A ligament, to be firm, and white and strong, must have only its natural degree of vascularity; but if it be inflamed with its increase of vascularity, it becomes of a grey colour, and softer, and loses its power of resistance. This condition of the ligaments of the hip-joint permits

dislocation, but does not cause it. It is the inclination of the body and the leg, which throws out the head of the bone from the socket; and owing to the softening and yielding of the ligaments, there is no check or limit to the distortion, and thus dislocation is consequent upon injury.

W. Cocks

PLATE K. 10 a.

Dislocations of the Foot.

These sketches represent a dislocation of the lower head of the tibia, and fracture of the fibula.

The tibia may be dislocated from the astragalus inwards or outwards; forwards, or backwards; and either of these luxations may be complete or incomplete.

The dislocation inwards is the most common.

Inwards.—The sole of the foot is turned outwards, and the back inwards.

Outwards.—The sole is turned inwards and the back outwards.

Forwards.—Diminution of length of the foot between the lower head of the tibia, and the extremity of the toes.

See Pages 413, 414, 415, 416.

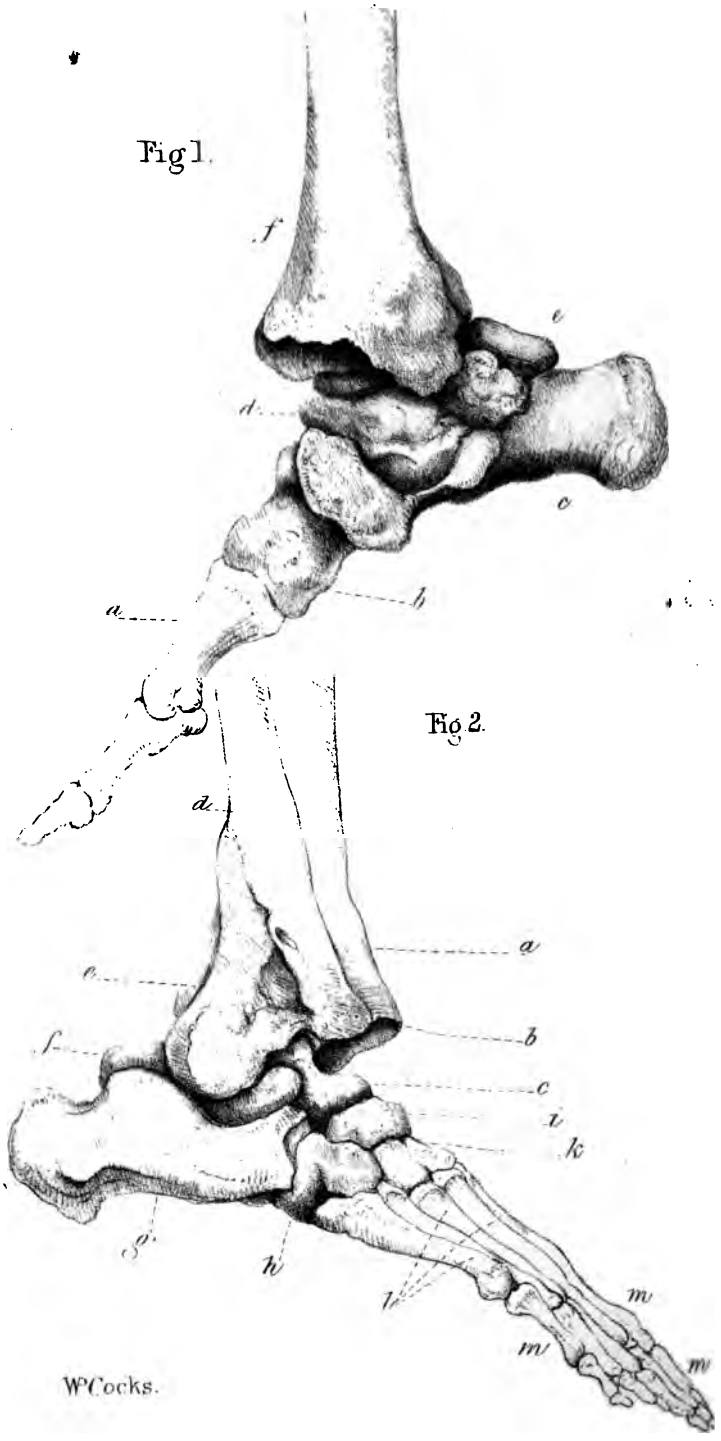
Fig 1.
f
e
d
c
a
b
Fig 2.
d
a
e
b
f
c
i
k
g
h
l
m
m'
m''
W Cocks.

PLATE K. 10 b.

Partial Dislocation of the Tibia forwards at the Ankle-joint.

Fig. 1.

a. Metatarsal bone of the great toe.
b. Internal cuneiform bone.
c. Os calcis.
d. Astragalus.
e. The original articulating surface of the astragalus.
f. The tibia.

Fig. 2.

a. The tibia.
b. New articulating surface of the tibia.
c. Astragalus.
d. Fibula.
e. The malleolus externus of the fibula, which had been broken off, and has been irregularly united.
f. The former articulating surface of the astragalus.
g. Os calcis.
h. Os cuboides.
i. Os naviculare.
k. The cuneiform bones.
l. The metatarsal bones.
m. The phalanges of the toes.

See page 413 to 416.

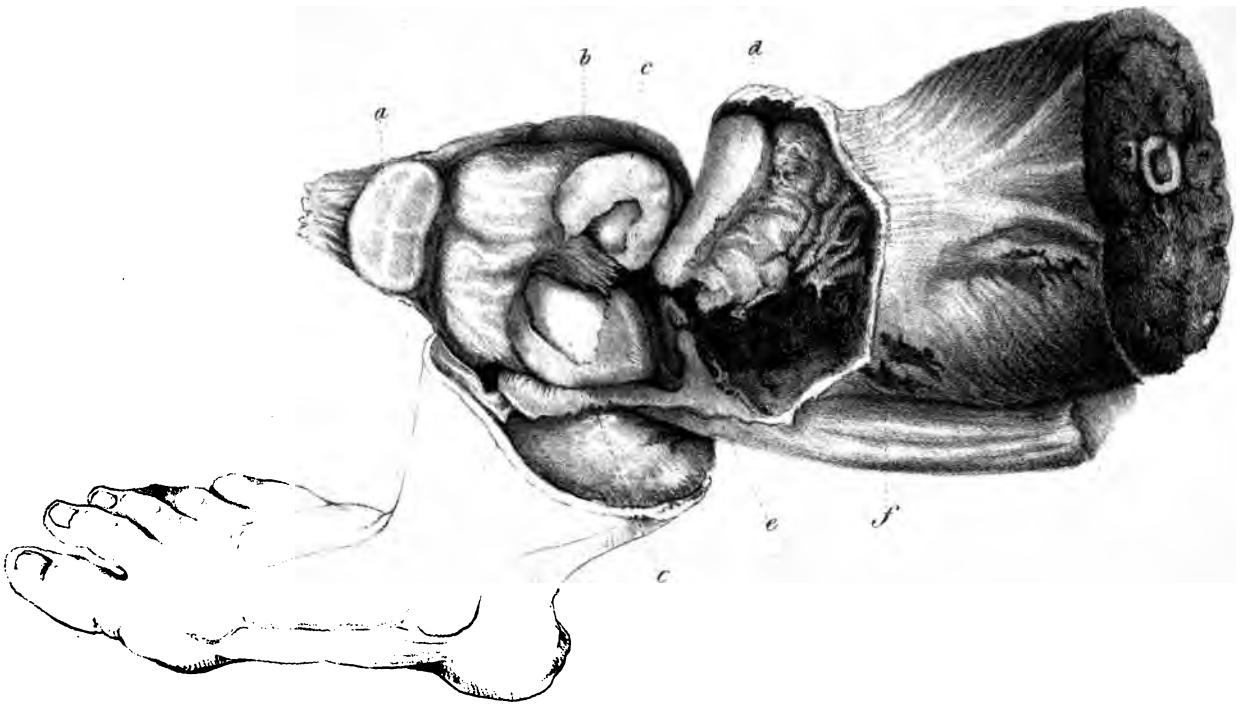
a
b
c
d
e
f
g

PLATE 11. K.

DISLOCATION OF THE KNEE-JOINT,

In which the thigh-bone was thrown outwards and backwards.

a. Patella,
b. Head of the tibia.
c.c. Semilunar cartilages.
d. Articular surface of the os femoris.
f. Lacerated vastus internus muscle.
g. Place of amputation.

See page 413

PLATE. 11. K. a.

Compound Dislocation of the Ancle-joint.

a. The lower end of the tibia protruding through the integuments.

b. Lacerated edges of the skin and integuments.

c. The sole of the foot turned outwards and upwards.

See page 386.

Plate XII a.

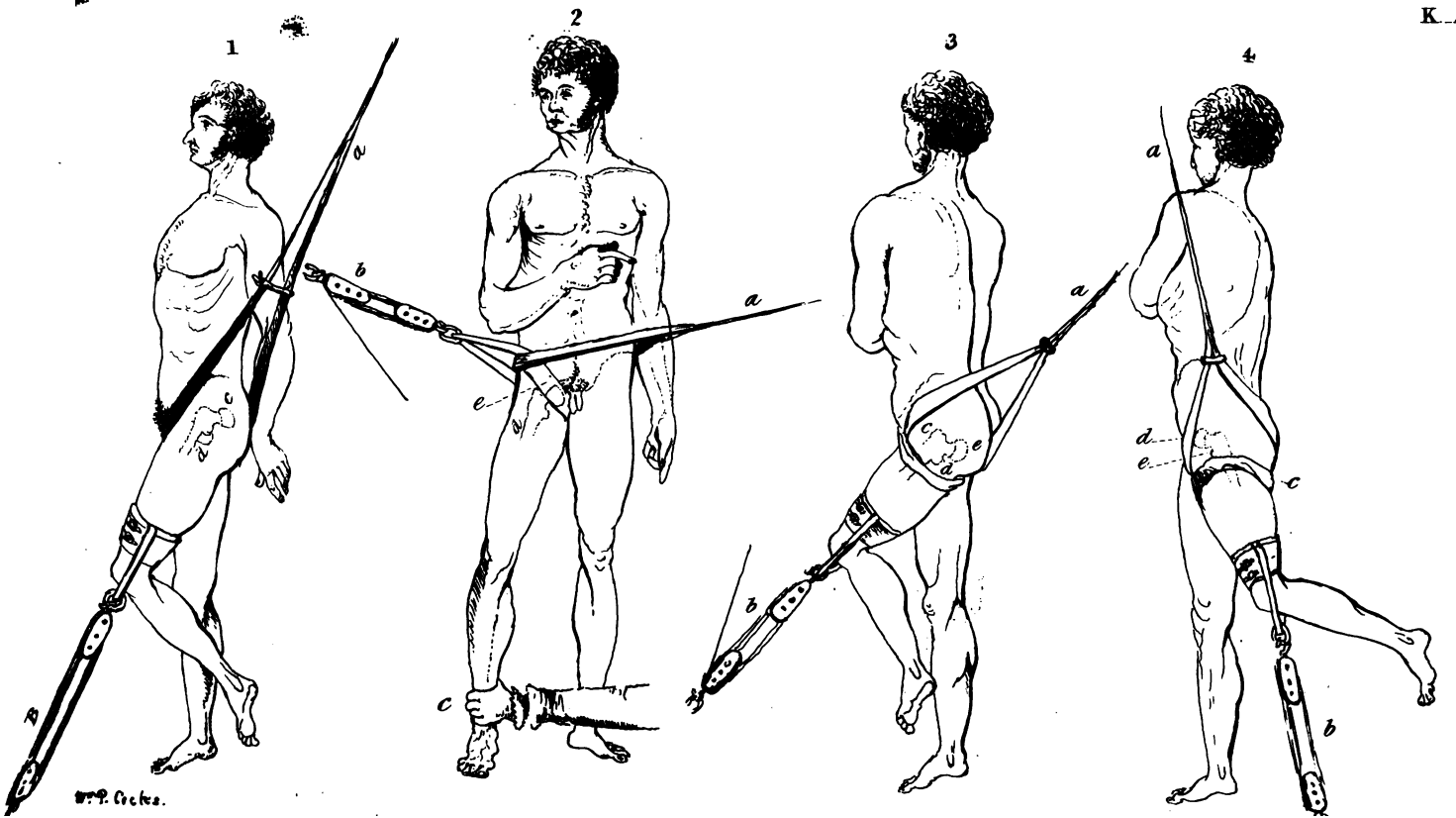
1
2
3
4
a
b
c
d
e
W. P. Cockes.

PLATE 12. K.

Fig. 1.

*The Mode of reducing the Dislocation upwards on the Dorsum Ilii.**

a. The bandage passed between the thighs to fix the pelvis.

b. The pulley fixed above the knee, and the direction shown in which the thigh is to be drawn, viz. obliquely across the sound thigh, two-thirds of its length downwards.

c. Head of the bone upon the dorsum ilii.

d. Acetabulum.

Fig. 2.

The Mode of reducing Dislocation into the Foramen Ovale.†

a. Bandage to fix the pelvis.

b. The pulley to draw the head of the os femoris outwards and upwards.

c. The surgeon's hand grasping the ancle to draw the one leg across the other, and to throw the head of the bone outwards.

d. Head of the bone in the foramen ovale.

e. Acetabulum.

* See page 409. † Page 410.

Fig. 3.

*The mode of reducing Dislocation into the Ischiatic Notch.**

a. The bandage which fixes the pelvis, and which passes between the thighs.

b. The pulleys fixed above the knee and extending in a direction across the middle of the sound thigh.

c. A band surrounding the thigh, by which the surgeon is to elevate the bone when the extension has been for some time continued.

d. Acetabulum.

e. The head of the bone in the ischiatic notch.

Fig. 4.

The Mode of reducing Dislocation on the Pubes.†

a. The bandage to fix the pelvis passing upwards and forwards.

b. The pulleys which draw the bone downwards and backwards.

c. A band passed round the thigh to enable the surgeon to raise the head of the bone during the extension.

d. The head of the os femoris on the pubes.

e. The Acetabulum ; above and before which the head of the bone rests upon the junction of the pubes and ilium.

* See page 411.—† See page 411.

Fig. 1.

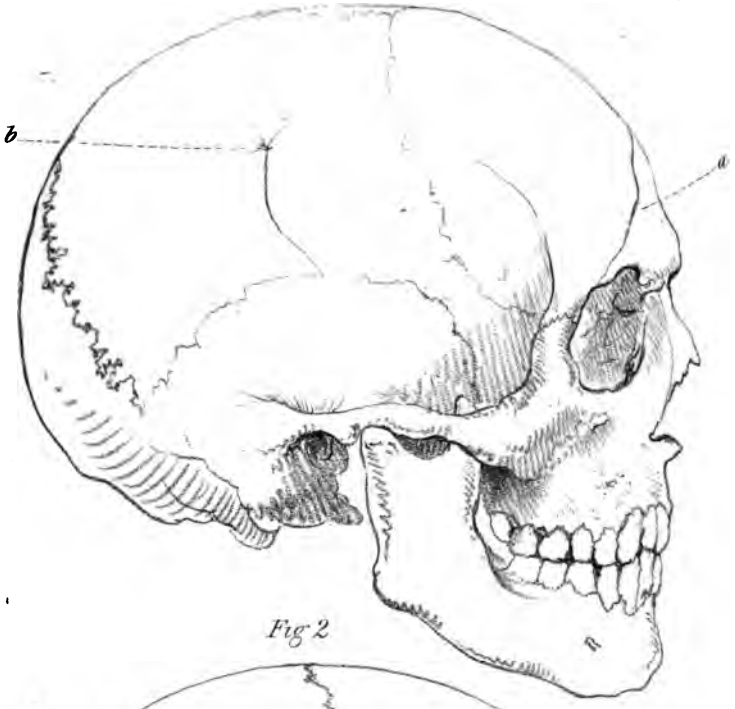

Fig. 2

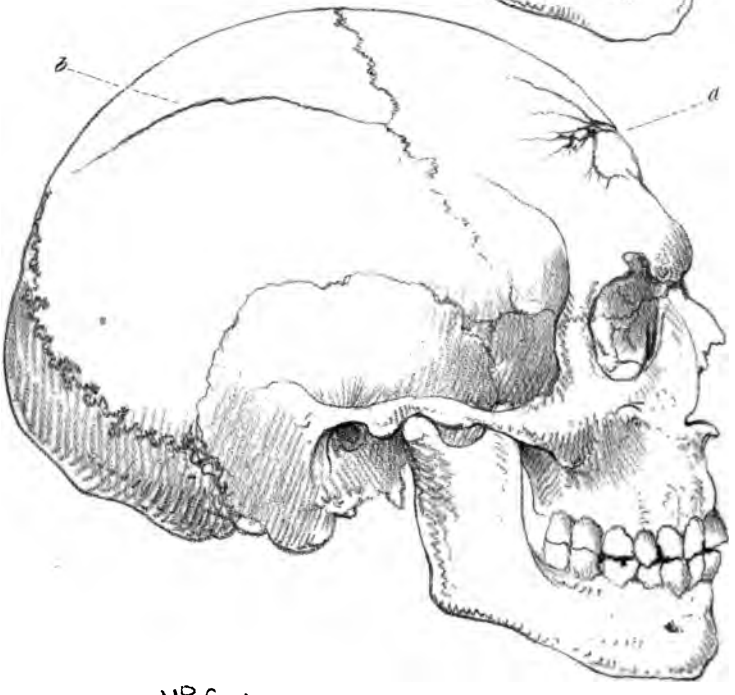

W. P. Cocks.

PLATE 13. K.

Fissures and Fractures of the Cranium, without Depression.

Fig. 1.

a. An oblique fissure of the frontal bone.
b. Fracture of the right parietal bone.

Fig. 2.

a. Extensive fracture of the frontal bone.
b. Fracture of the parietal bone, the course of which is stopped by the coronal suture.

See page 607.

PLATE 14. K.

This plate represents extensive Injuries of the Skull.

Fig. 1.

A. A portion of the integuments on the left side of the head thrown back.

b. Parietal bone exposed.

c. Depressed portion of bone.

Fig. 2.

A. A portion of the pericranium removed so as to expose the surface of the parietal bone.

b. The lateral and posterior portions of the parietal bone, on the left side of the head, completely smashed, and the fragments buried in the cortical part of the brain.

c. The integuments thrown over the occiput.

See page, 609.

Fig 1

Fig 2.

Fig 1.

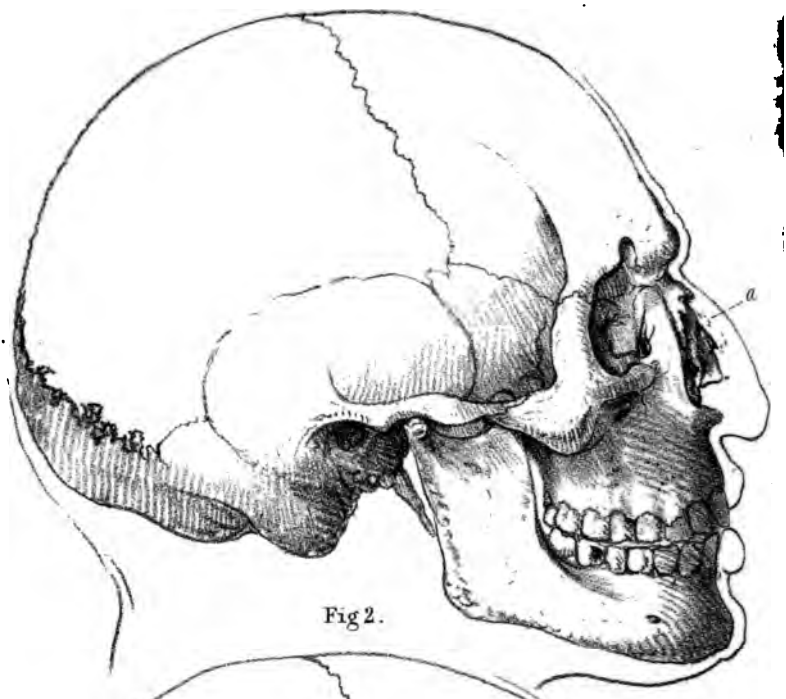

Fig 2.

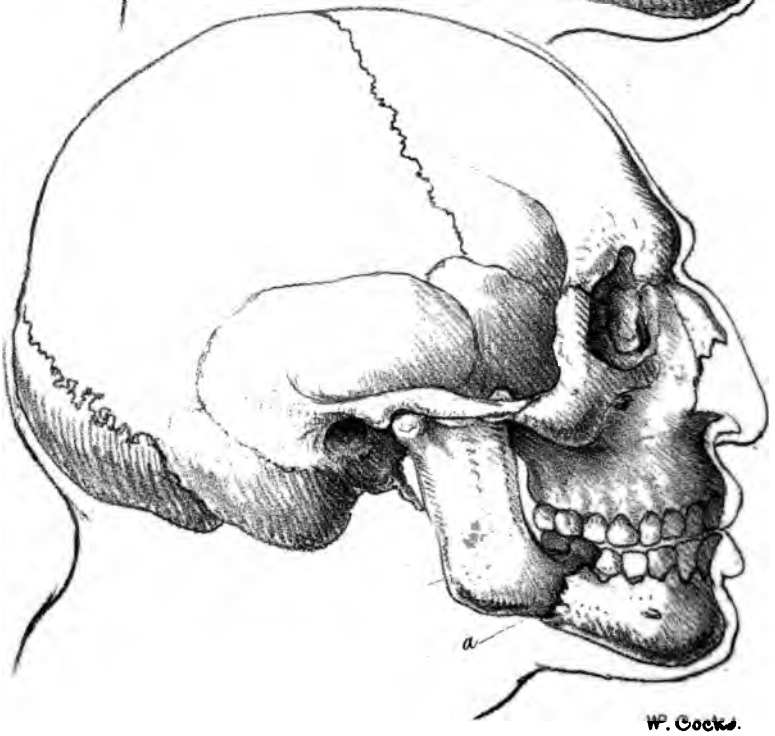

W. Cocks.

PLATE K. 15.

Fractures of the Bones of the Face.

Fig. 1.

The right nasal bone broken to pieces and depressed.

The nasal bones, from their prominent situation, are much exposed to fractures. The fragments are sometimes not deranged; but most frequently they are depressed.

See page 506.

Plate K 16.

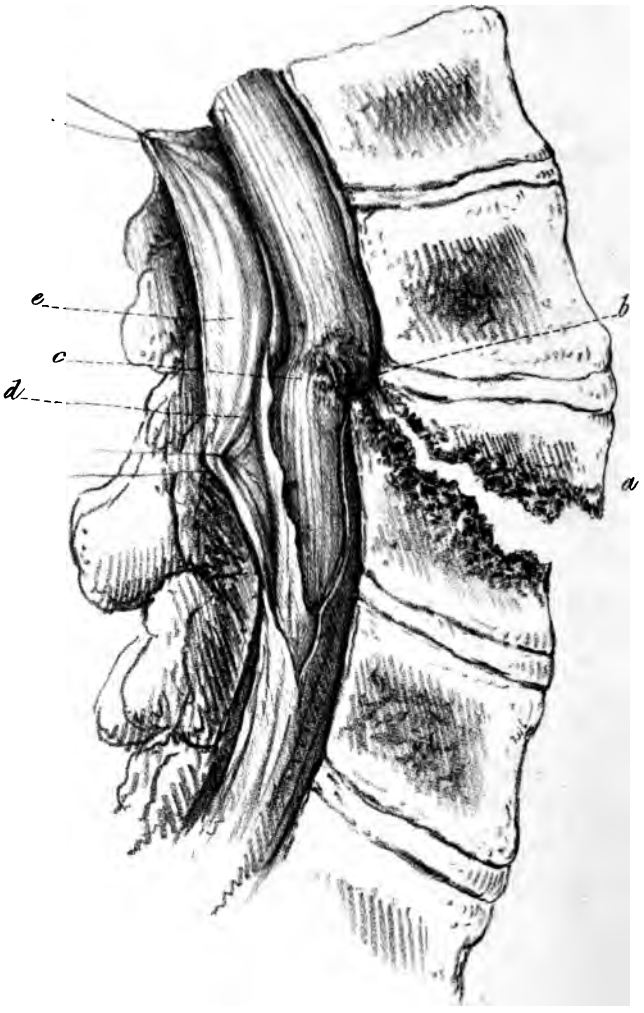

W^P Cocks.

PLATE K. 16.

*Fracture of the Body of the Ninth Dorsal Vertebra.**

a. The superior portion of the fractured vertebra.

b. Extravasated blood lying between the pia mater and the spinal marrow.

c. The spinal marrow bruised and compressed by the superior portion of the lower half of the fractured bone.

d. Pia mater, or proper sheath† of the spinal marrow.

e. Dura mater. All the spinal nerves are removed in this preparation.

* The bodies of the vertebræ are not fractured by blows, but by falls, in which the whole body is twisted, as when a bank of earth falls upon and buries a man. This fracture will not be known by the crepitation, like a common fracture of the limbs, but only by the derangement of the projecting spinous processes.

† As the pia mater descends into the spinal canal, it becomes firm, resistant, and much paler in colour. Its inner surface is in close contact with the medulla, the exterior is but slightly connected to the arachnoid, and the nerves, at the different points at which they pass outwards, derive from it their immediate investment or neurilema.

See pages 507 to 509.

Treatment.—Any attempt to set fractures of the bodies of the vertebræ, even where they are known to exist, would be both useless and dangerous; for in whatever way the vertebræ are broken, the danger must be apparent, since, in every change of posture, or turn of the body, the broken bones may be thrust against the spinal marrow. General treatment can alone be employed. Cupping, or leeches, will tend to prevent inflammation in the situation of the injury. In case of flatulent distension of the abdomen, vomiting, hiccough, &c., the belly may be rubbed with camphorated liniment, purgative clysters, and antispasmodics given.

When called to a patient in this situation, the surgeon must provide himself with a catheter to draw off the urine, because he knows that the sensibility of the bladder is destroyed, and that there will be in a short time an accumulation of urine.

Plate K.17

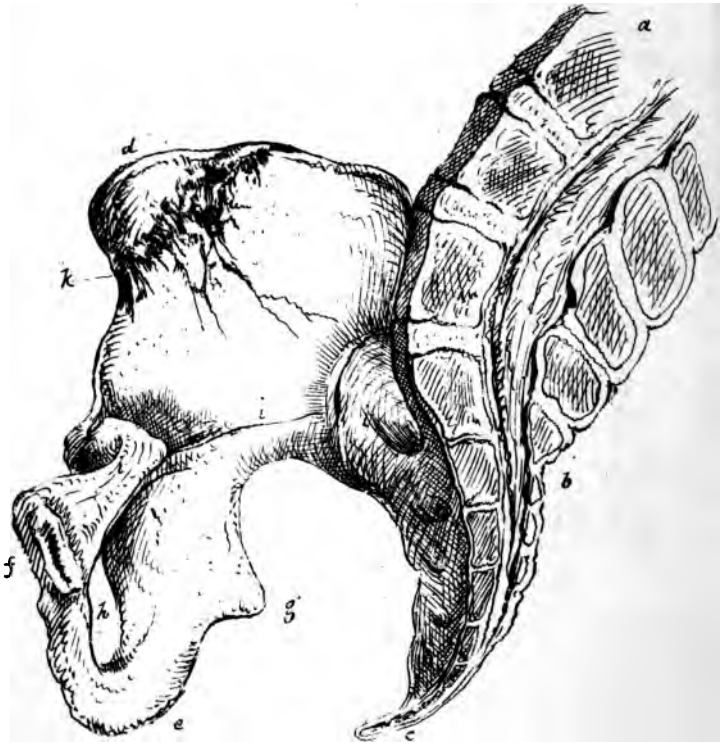

W. P. Cocks

PLATE K. 17.

Fracture of the Ilium on the Right Side.

a. to *b.* Lumbar vertebræ.
b. Os sacrum.
c. Os coccygis.
d. Spinous process of the ilium.
e. Os ischium.
f. Os pubis.
g. The acute process of the os ischium.
h. Foramen ovale.
i.i. Brim of the pelvis.
k. The fractured portions.

See pages 511, 512.

PLATE K. 18.

Fracture and Separation of the Bones of the Pelvis.

Fig. 1.

An oblique fracture, passing through the body of the pubes and ramus of the ischium.

Fig. 2.

Separation of the ossa pubis at the symphysis.

See pages 511, 512.

Plate K.18.

Fig 1.

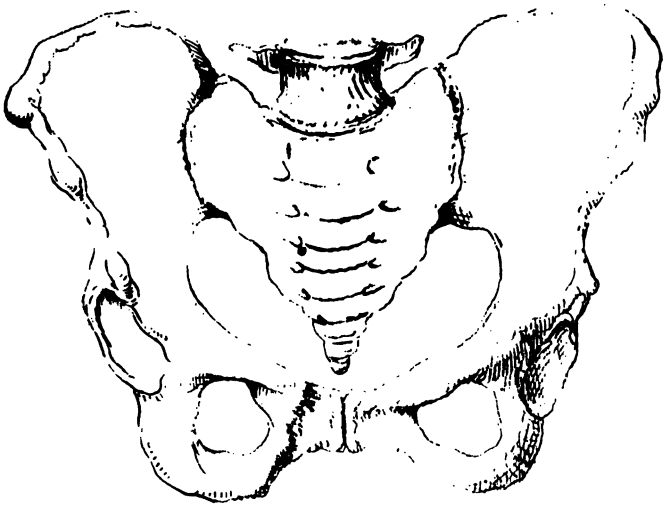

Fig 2.

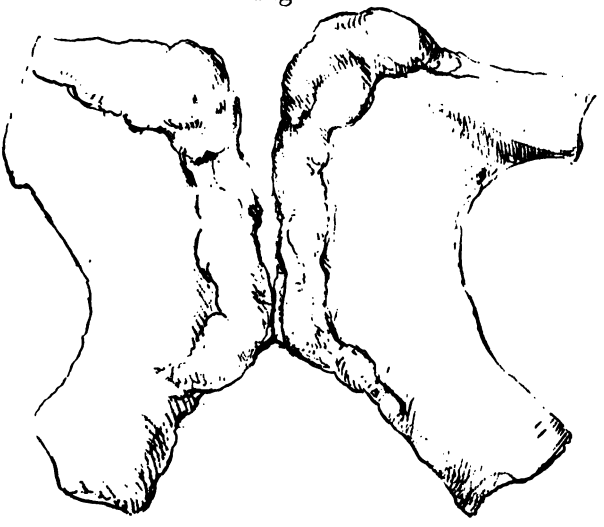

W. Cocks

K. Plate. 19.

Fig 2

Fig 4

Fig 3

Fig 1

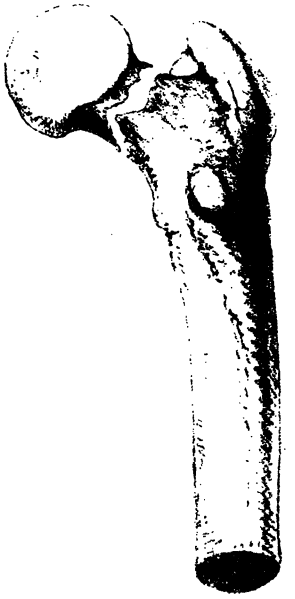

W. Cocks.

PLATE K. 19.

This plate represents fractures of the neck of the thigh-bone.

Fig. 1.

Fracture of the cervix femoris within the capsule.*

Fig. 2.

Fracture of the cervix femoris within, and the trachanter major without, the capsular ligament.

Fig. 3.

Fracture of the trochanter major.†

Fig. 4.

Fracture of the trochanter major and minor.§

* Page 517 † Page 519. § Ibid

PLATE K. 20.

Fractures of the Middle and Lower Third of the Thigh-bone.

Fig. 1.
An oblique fracture of the thigh-bone.

Fig. 2.
Transverse fracture of the thigh-bone.

Fig. 3.
An oblique fracture of the external condyle of the femur.

Fig. 4.
Fracture of the internal condyle of the femur.

See pages 512, 523.

Plate K

1

2

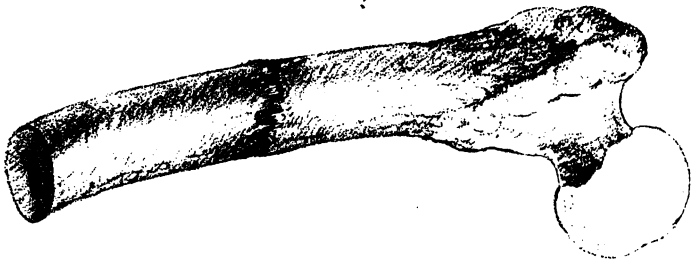

3



4

W. Cooke.

Fig 2

Fig 1.

W^P. Cocks

PLATE K. 21.

Fractures of the Bones of the Leg and Foot.

Fig. 1.

Transverse Fracture of the tibia and fibula.

Fig. 2.

An oblique fracture of the shaft of the tibia.

See pages 526 to 529.

PLATE K. 22.

Fractures of the Bones of the Foot.

Fig. 1.

Fracture of the metatarsal bone of the great toe.

a. Astragalus.
b. Middle cuneiform bone.
c. Internal ditto.
d. Os naviculare.
f. The fractured metatarsal bone.
g. Phalanges of the toe.

Fig. 2.

Comminuted fracture of the astragalus.

Fig. 3.

Comminuted fracture of the metatarsal bones of the foot, by the passing of a cart wheel over them.

a.a. The fractured metatarsal bones.
b. The os cuboides.
c. The three cuneiform bones.

Fig 1.

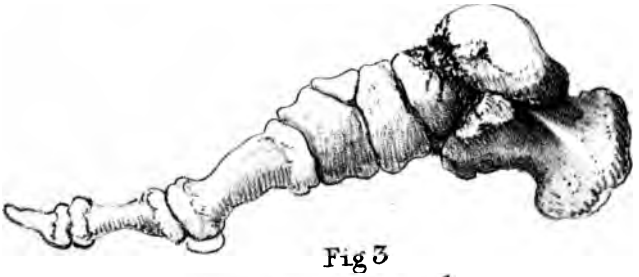

Fig 3

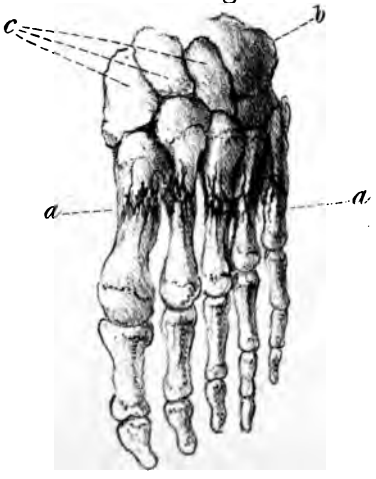

Wm. Cocks.

Plate K 23.

Fig 1.

Fig 2.

Fig 3.

W P Cocks

PLATE K. 23.

Fractures of the Scapula.

Fig. 1.

Fracture of the cervix scapula.

a.a. Inside of the scapula.
c. Acromion process.
e. The coracoid process.
f. The edge of the glenoid cavity.
g. The glenoid cavity broken off by a fracture through the neck of the scapula.

See pages 529, 530.

Fig. 2.

Fracture of the acromion process.

f. Glenoid cavity of the scapula.
h. That portion of the acromion process broken off to which the clavicle is articulated.

Fig. 3.

Longitudinal fracture of the body of the scapula.

Fig. 1.

Fig. 2.

Fig 3.

W. Cocks

PLATE K. 24.

This plate represents fractures of the os brachii.

Fig. 1.

Fracture of the head or neck of the os humeri.

Fig. 2.

Fracture of the internal condyle of the os humeri.

Fig. 3.

Fracture of the external condyle of the os humeri.

See pages 532 to 535.

PLATE K. 25.

Fractures of the middle of the os brachii and separation of the condyles.

Fig. 1.

Separation of the condyles from the shaft of the os humeri.

Fig. 2.

Transverse fracture of the shaft of the os humeri.

Fig. 3.

An oblique fracture of the shaft of the os humeri.

See pages 532 to 535.

Fig 1.

Fig 2.

Fig 3.

W.P.Cocks.

Fig 1.

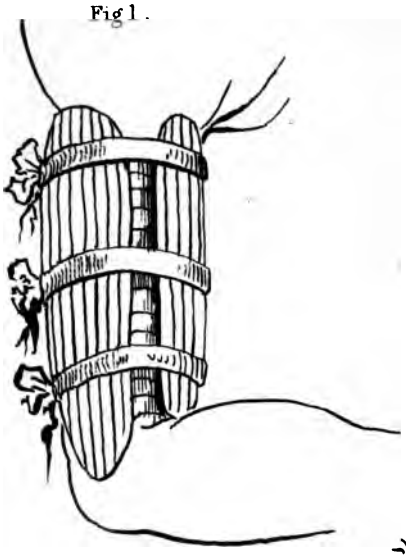

Fig 2

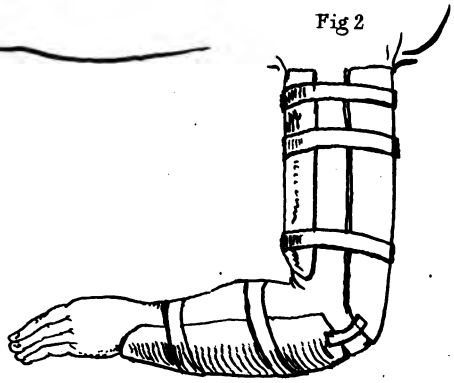

Fig 3

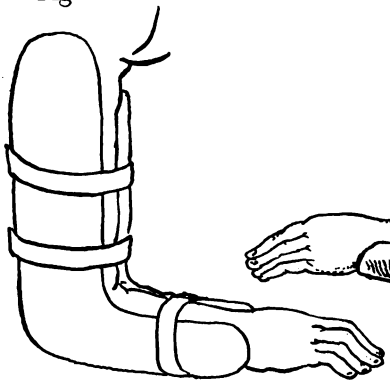

Fig 4

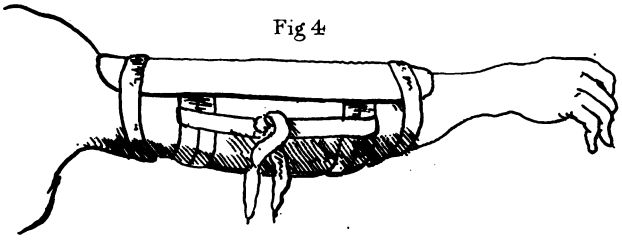

Wm. Cocks.

PLATE K. 30 b.

Fig. 1.

The method of bandaging a fractured arm.

Fig. 2.

Splints for fractures of the condyles.

Fig. 3.

Splints for fractures of the elbow-joint.

Fig. 4.

Splints and bandages for fracture of the Olecranon.

See pages 533, 534, 535, 537, 538.

PLATE. K. 30 c.

These sketches represent the inclined plane that is in general use, for simple fractures of the thigh and trochanter major.

See page 516.

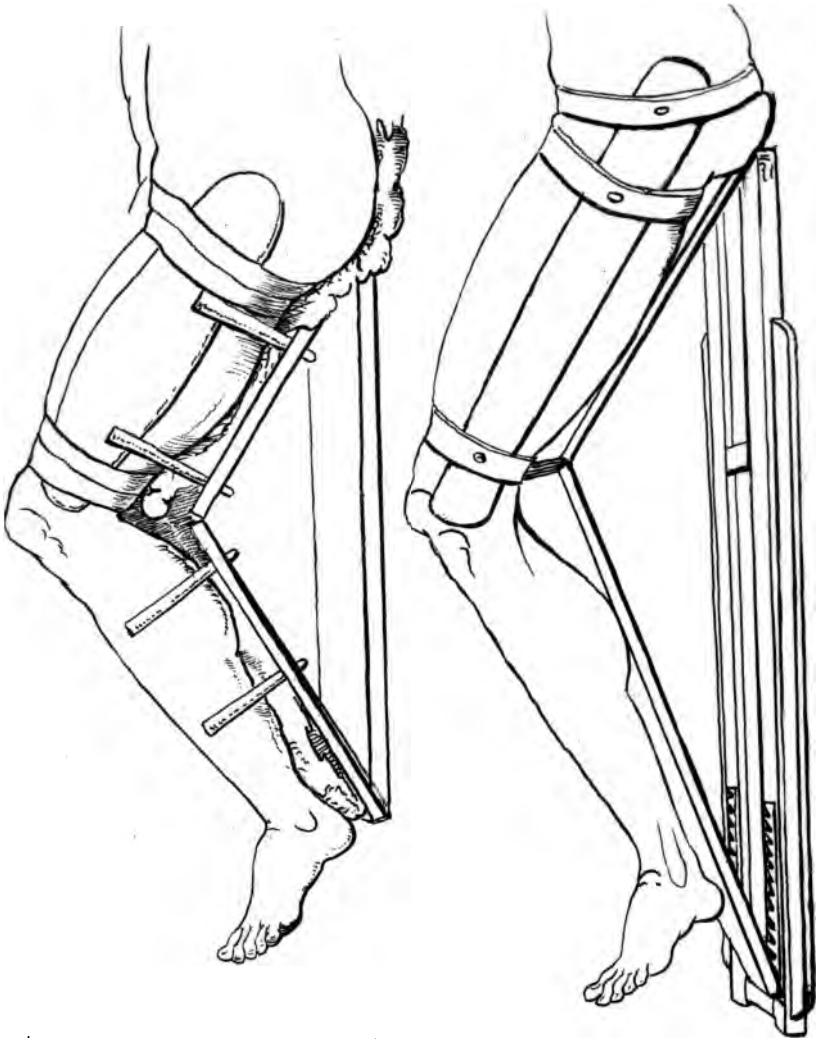

W. Cocks.

Fig 1.

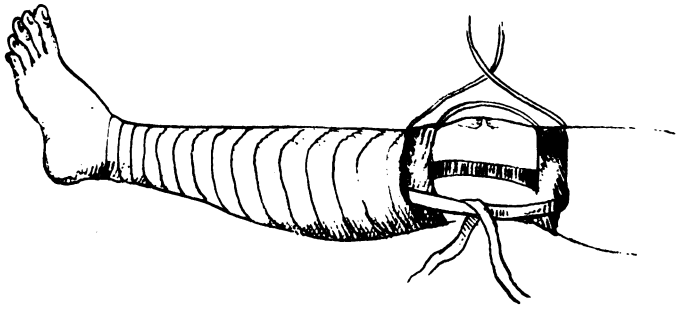

Fig 2.

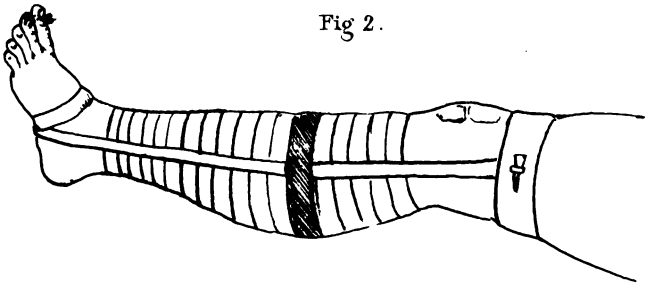

Fig 3.

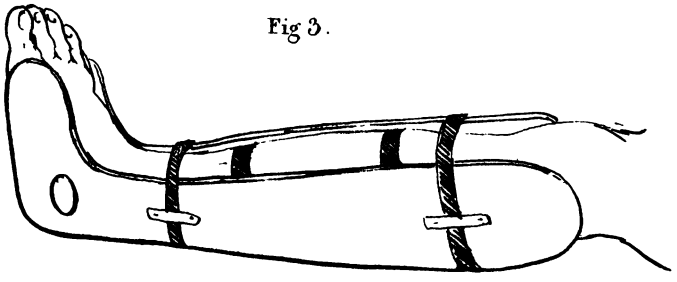

PLATE K. 30 d.

Fig. 1.

Bandages for fractured patella.*

Fig. 2.

A leather strap buckled above the patella, with another strap passing under the foot.

Fig. 3.

Splints, with a foot-piece on each side, for dislocations† and fractures‡ at and near the ankle-joint.

* See pages 524, 525. † Pages 415, 416. ‡ Pages 528, 529.

PLATE K. 30 e.

The mode of applying the many-tailed bandage in fractures of the thigh and leg.

See page 224.

Plate K 30 e.

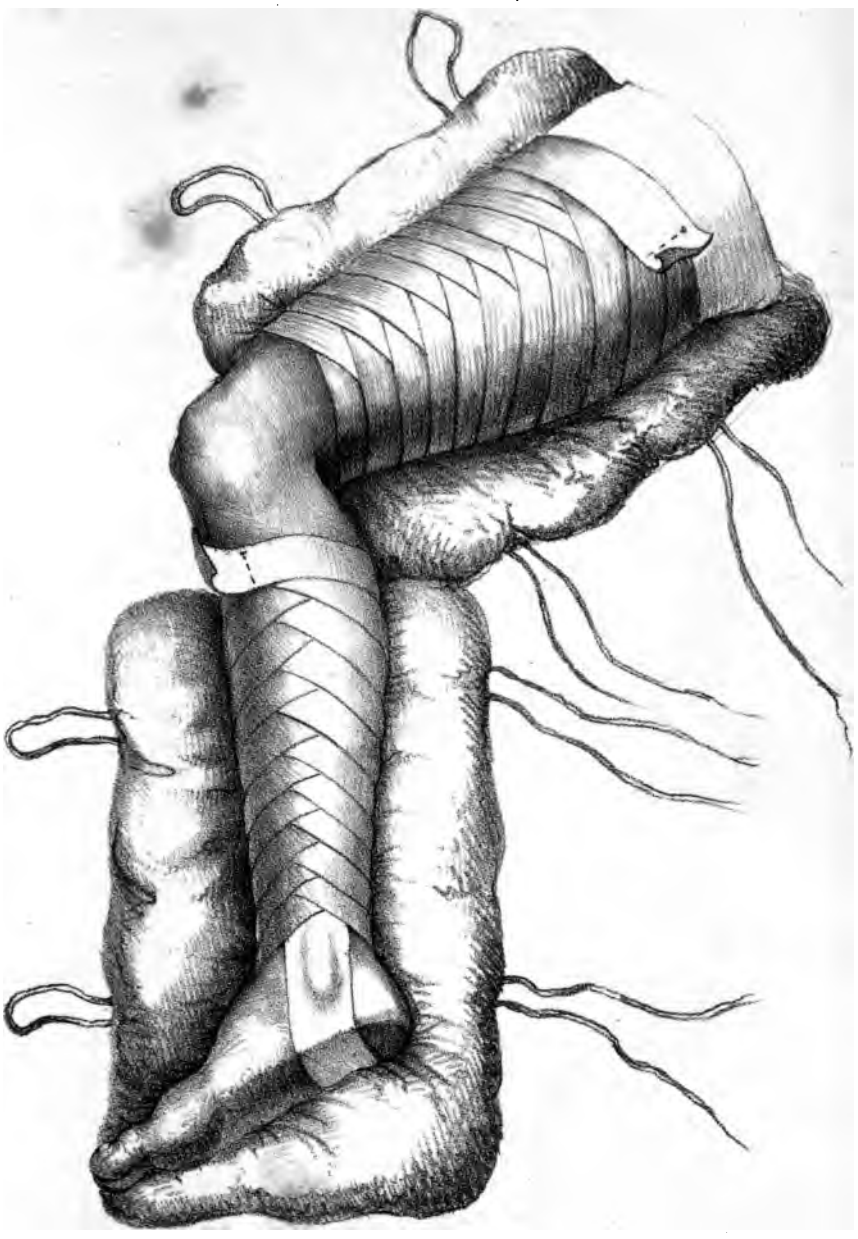

W. Cocks.

K. *Plate 37.a.*

W. Cocks.

PLATE K. 37 a.

Anchylosis of the Hip-joint.

a. Ilium.
b. The head of the thigh-bone firmly united to the acetabulum
c. The trochanter major.
d. The trochanter minor.
e. The Ischium.

See page 109

PLATE K. 37 b.

Anchylosis of the Knee-joint.

a. The patella.
b. The outer condyle.
c. The inner condyle.
d. A large portion of new bony matter firmly uniting the internal condyle of the os femoris to the patella and head of the tibia.
e. Tibia.
f. Fibula.

See page 109.

Plate K. 37. b.

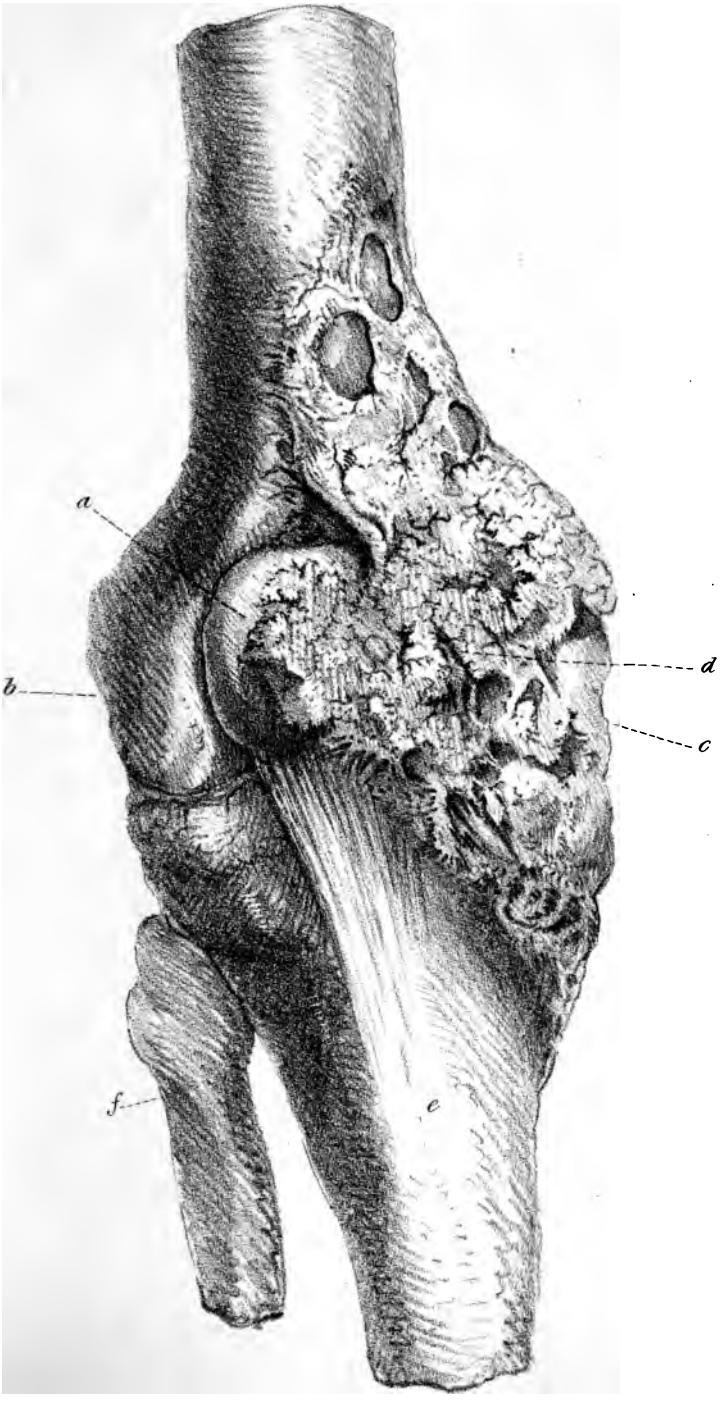

W. Cock

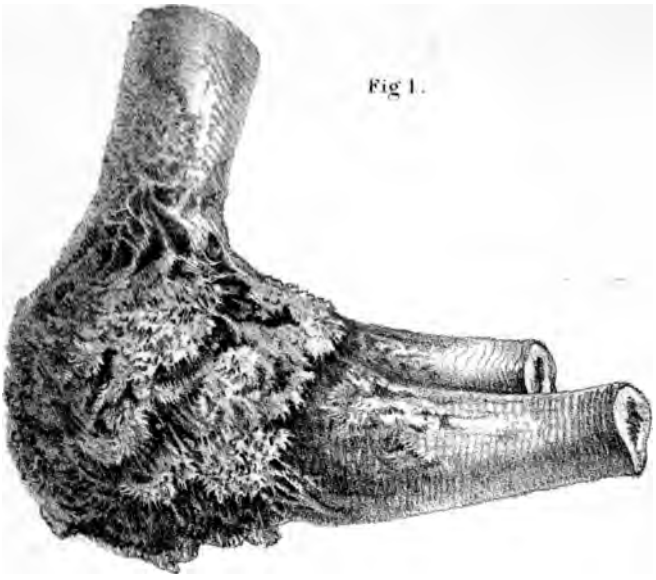

Fig 2.

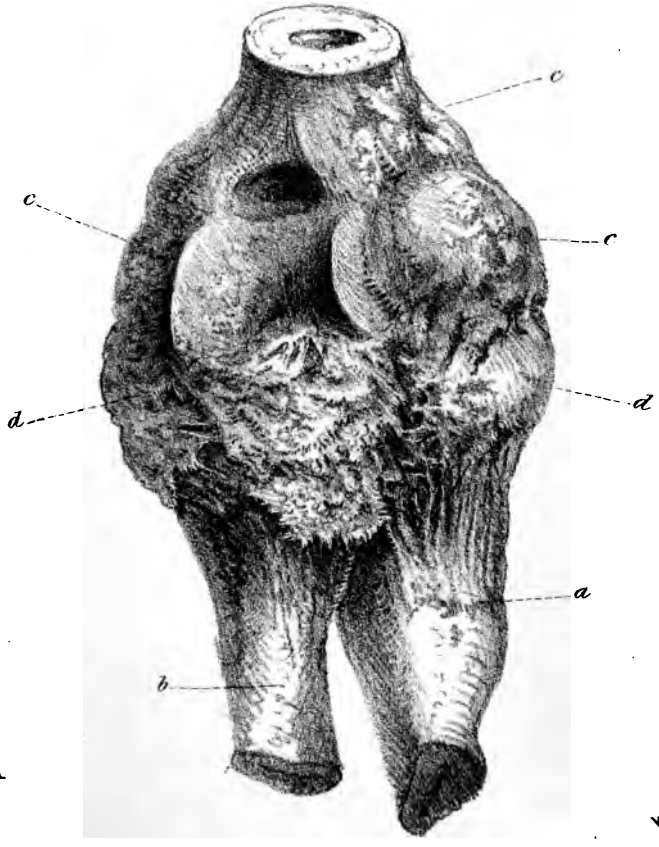

W.P. Cocks.

PLATE K. 37 d.

Anchylosis of the Elbow-joint.

Fig. 1.

Anchylosis of the humerus to the ulna.

Fig. 2.

Anchylosis of the humerus with the radius and ulna.

a. Ulna.

b. Radius.

c.c.c. Various portions of the humerus affected with caries.

d.d. New bony matter uniting the three bones of the elbow-joint.

See page 109.

PLATE K. 37 e.

Caries of the joint of the wrist, the bones united by anchylosis: the disease is represented in two figures, in order to demonstrate a complete union of the carious joints.

See page 109.

Plate K.37 e.

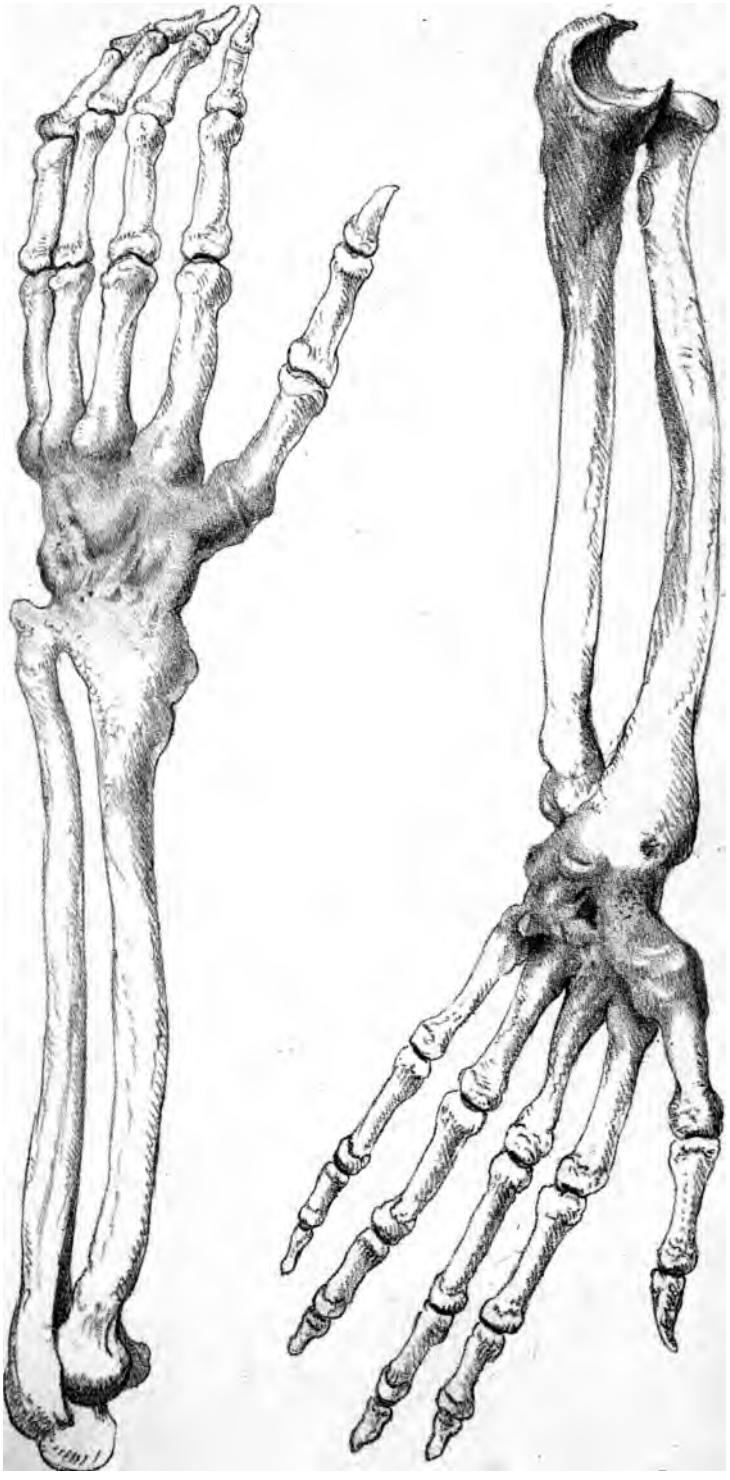

GUN-SHOT WOUNDS.

GUN-SHOT wounds are the most considerable of the contused kind. They are particularly characterized by what the French surgeons are fond of calling, a disorganization of their surface. The excessive contusion, and violence, observable in them, depend upon the rapidity with which the bodies occasioning them are propelled.

If a musket or pistol-ball has struck a fleshy part, without injuring any material blood-vessel, we see a hole, about the size of, or smaller than, the bullet itself, with a more or less discoloured lip, forced inwards, and, if it has passed through the parts, we find an inverted edge, and a more ragged and larger orifice at the point of its exit. The hemorrhage is in this case very slight, and the pain inconsiderable, insomuch that, in many instances, the wounded man is not aware of his having received any

injury. If, however, the ball has torn a large vessel, or nerve, the hemorrhage will generally be profuse, or the pain of the wound severe, and the power of the part lost.

See pages 462 to 586.

Fig 1.

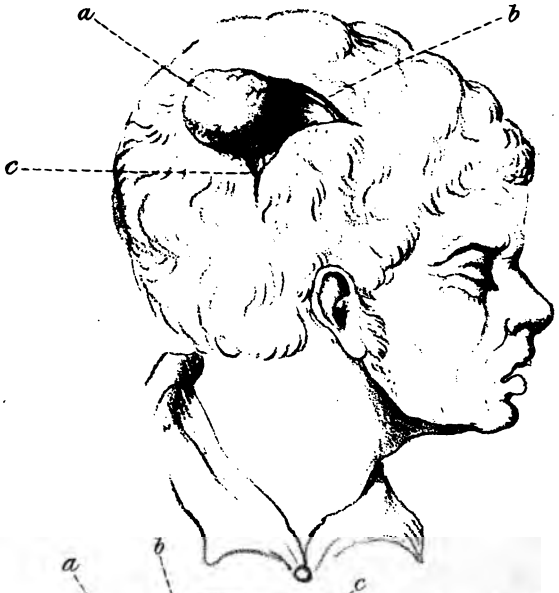

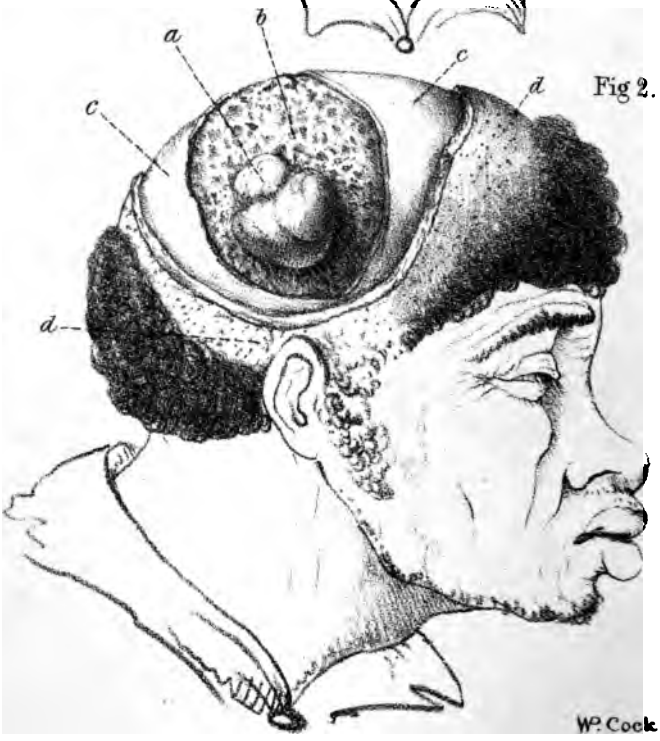

Fig 2.

Wm. Cocks.

PLATE R. 1.

Fungus cerebri from gun-shot wound of the head and caries of the bones of the cranium.

Fig. 1.

Fungus cerebri from gun-shot wound of the right parietal bone of the head of a young man.

a. A portion of the cerebral matter projecting through the injured part of the skull.

b. Fractured portions of bone.

c. The integuments of the head.

See pages 562 to 586.

Fig. 2.

Fungus cerebri from an extensive destruction of the bone and membranes of the head of a negro.

a. A portion of cerebral matter, as large as a hen's egg, projecting through the carious bone.

b. Honey-comb appearance of the bones of the head.

c.c. Pericranium thickened and of a fibro-ligamentous texture.

d.d. Integuments of the head.

See pages 562 to 586.

R. *Plate 2.*

PLATE R. 2.

Gun-shot Wound of the Arm.

The arm carried off near the shoulder joint by a round shot.

See pages 562 to 586.

PLATE R. 3.

Pistol-shot Wound of the Chest.

The ball entered two inches and a half above the nipple on the right side of the chest, and passed through the lungs and integuments of the back.

See page 585.

Plate R 3

W. C.

Plate R.4.

PLATE R. 4.

Gun-shot Wounds of the Abdomen.

This sketch represents several buck-shot wounds of the abdomen.

Gun-shot wounds of the belly may be divided into two kinds; one only penetrates the parietes of the belly without hurting the contained parts; the other does mischief also to the viscera. The event of these two kinds of wounds is very different. In the first, little danger is to be expected, if properly treated; but, in the second, the success will be extremely uncertain; for, in many instances, nothing can be done for the patient, and on other occasions a good deal. Mr. Hunter states, that such wounds of the abdomen as do not injure parts like the stomach, intestines, bladder, uterus, gall-bladder, large blood-vessels, &c., all which contain particular fluids, will generally end well. But, he adds, that that there will be a great difference when the ball has passed with immense velocity, as a

See pages 282 to 285.

slough will be produced; whereas, when the ball has moved with less impetus, there will not be so much sloughing, and the parts will in some degree heal by the first intention. Even when the ball occasions a slough, the wound frequently terminates well, the adhesive inflammation taking place in the peritoneum all round the wound so as to exclude the general cavity of the abdomen from taking part in the inflammation. Such is often the favourable event when the ball, besides entering the abdomen, has wounded parts like the omentum mesentery, &c. and gone quite through the body.

See pages 282 to 285.

HERNIA.

By the term Hernia, is understood a protrusion of a soft part from any of the three principal cavities of the body in which it was naturally contained. But as abdominal herniæ occur more frequently than any other, the term hernia is in general confined to a tumour formed by the displacement of the viscera contained in that cavity. There is hardly any disease, which is more frequent, more diversified in degree, species, and complication, and requiring greater judgment, caution, decision, and experience on the part of the surgeon. Hernia has been defined a tumour caused by the protrusion of one or more of the viscera from the abdominal cavity into a sac; which sac is formed by the peritoneum, the investing membrane of that cavity, covered by the common integuments, and sometimes certain fasciæ.

In abdominal herniæ, the bowels are generally protruded through what may be called natural openings; and there are, also, herniæ of the belly, which appear where there is no natural opening, and, in these cases, there is gene-

rally a rupture of the fibres of the muscles which constitute the parietes of the abdomen.

There are several kinds of abdominal herniæ; five of which, however, are more frequent than the others; viz. the inguinal, the congenital, the femoral, the umbilical, and the ventral.

I. Hernia, through the inguinal canal.

The common, or external inguinal hernia, as it is called by Hesselbach, commences at the point, where the spermatic cord passes under the lower edge of the transverse muscle, and, passing through the inguinal canal, protrudes at the abdominal ring; the opening in the tendon of the external oblique muscle, by which, in the male subject, the spermatic cord passes outwards, and in the female, the round ligament of the uterus.

There are six varieties:

Inguinal hernia, arrested in its first stage of descent, being in the inguinal canal, but not external to the abdominal ring.

Inguinal hernia (bubonocele), when the bowel just protrudes, and lodges in the groin.

Scrotal hernia (oscheocele), when the bowel descends into the scrotum.

Hernia of the labium pudendi,—when the bowels descend through the ring in women. A hernia may be lodged here which has come down by the side of the vagina.

Hernia, where the protrusion occurs, not

through the whole of the inguinal canal, but more directly through the abdominal ring, after having forced a passage through the aponeurosis of the internal oblique and transverse muscles, near the pubes, within the point where the spermatic cord crosses the epigastric artery. The internal inguinal hernia, of Hesselbach.

Hernia through the ring and through the spermatic process of the peritoneum; being in contact with the testicle, and congenital, or appearing at birth, or at least with the descent of the testicle.

II. Hernia under the crural ligament; viz. crural or femoral hernia (merocele).

III. Umbilical hernia (exomphalos, omphalocele). This arises from a protrusion of the intestines through the opening in the linea alba, which is formed in the fœtal state for the passage of the vessels of the umbilical cord.

IV. Herniæ through any preternatural opening of the muscles of the belly or their tendons, are generally named ventral.

When the hernial sac contains intestine only, the tumour has been called enterocele; when omentum only, epiplocele; and when both omentum and intestine form the contents of the hernia, the term entero-epiplocele is applied. The terms gasterocele, hepatocele, splenocele, hysterocele, cystocele, are employed when the

stomach, liver, spleen, uterus, or bladder of urine form the contents of the hernial tumour.

Besides the commonforms of herniæ, there are some less frequent kinds, of which the following are examples :

Thyroideal Hernia.—In the anterior and upper part of the obturator ligament there is an opening, through which the obturator artery, vein, and nerve proceed, and through which occasionally a piece of omentum or intestine is protruded, covered with a part of the peritonæum, which constitutes the hernial sac.

Pudendal Hernia.—It commences at the side of the vagina, and passes into the labium between the vagina and ischium: it forms an oblong tumour, traceable within the pelvis, as far as the os uteri.

Vaginal Hernia.—Protrudes in the space left between the uterus and rectum.

Perineal Hernia.—In men, the parts protrude between the bladder and rectum; in women, between the rectum and vagina.

Ischiatic Hernia.—Passing out of the pelvis at the ischiatic notch.

Phrenic Hernia.—The abdominal viscera, passing through preternatural holes in the diaphragm, or through the dilated passage for the œsophagus.

Mesenteric Hernia.—If one of the layers of the mesentery be torn by a blow, while the other

remains in its natural state, the intestines may insinuate themselves into the aperture, and form a kind of hernia.

Mesocolic Hernia.—The intestines glide between the layers of the mesocolon.

In cases of reducible hernia, the protruded portions can be returned into their natural situations; but, in cases of irreducible hernia, although unaccompanied with inflammation, the parts cannot be returned into the cavity of the abdomen from the following causes:—

1st. Growth of the protruded omentum, or mesentery, rendering it too large to be returned through the orifice of the hernial sac.

2d. Adhesion of the omentum, mesentery, or intestine to the inner surface of the sac.

3d. Membranous bands formed across the sac.

4th. Omentum entangling the intestine.

5th. A protruded cœcum, in which the intestine adheres by cellular membrane behind, and the sac exists only on the fore part.

6th. A portion of omentum, suddenly protruded, of too large a size to be immediately returned.

Fig 1.

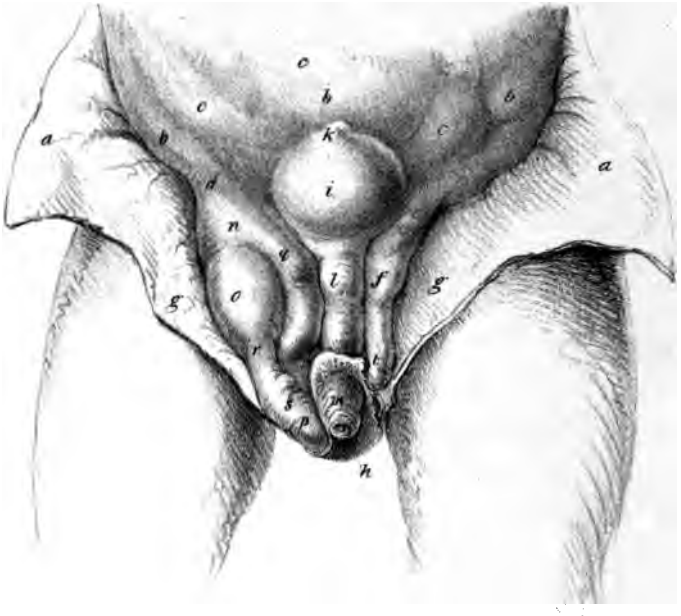

Fig 2.

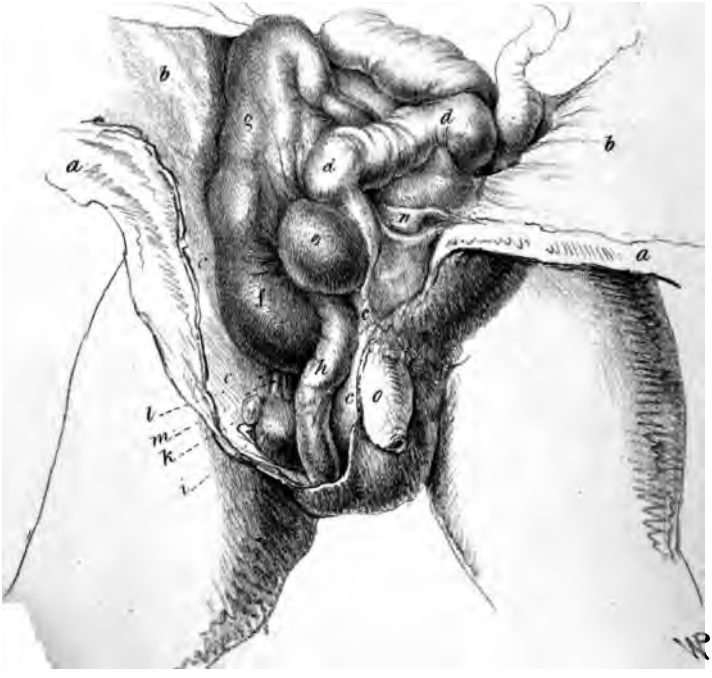

W.P. Cocks

PLATE. 1. T.

Fig. 1

Represents the peritoneum, freed from the integuments and muscles, extending on each side into the scrotum, and forming on the right a congenital hernia.

a.a. The layers of skin and muscles dissected and reflected.

b.b.b. The entire bag of the peritoneum, detached from the muscles.

c.c.c. The abdominal viscera distinguishable through the peritoneum.

d. The production of peritoneum on the right side dilated by the bowels protruded from the abdomen, and forming the hernia.

e. The other production of peritoneum in the left groin.

f. The place, where the latter production was closed, which is partially inflated, in order that the state of the parts may be better seen.

g.g. The skin of the scrotum reflected.

h. The bottom of the scrotum.

i. The bladder situated in front of the bag of the peritoneum.

k. The commencement of the urachus.

l. The penis, without integuments.

m. The prepuce.

n.o.p. The hernial sac, of different capacity at different points, extending to the bottom of the scrotum.

See page 677.

q. The ileum small intestine seen through the peritoneum.

r. The cœcum, also seen through the peritoneum.

s. The appendicula vermiformis.

t. The left testicle.

Fig. 2.

The peritoneum being opened, the contents of the abdomen and hernial sac are brought into view.

a.a. The integuments of the abdomen and scrotum, with the muscles reflected.

b.b. The layers of peritoneum reflected, shewing its very smooth internal surface.

c.c.c.c. The hernial sac.

d.d. The small intestines.

e. The end of the ileum.

f. The cœcum.

g. The colon.

h. The appendicula vermiformis, extending to the bottom of the scrotum, and adherent to the hernial sac.

i. The testicle.

k. The epididymis.

l. The spermatic vessels.

m. The vas deferens.

n. The bladder, drawn towards the left side, in order to let the contents of the hernial sac be better seen.

o. The penis.

See page 653.

Fig 1.

Fig 4.

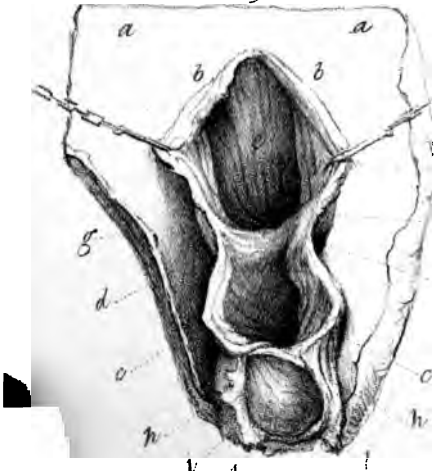

Fig. 3.

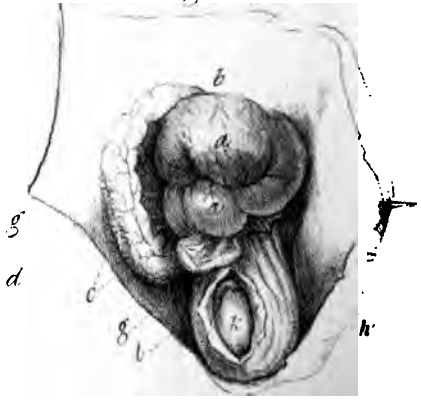

PLATE 2. T.

---

a.a. The left inguinal ring.

b.b. Intersection of the collateral tendinous bands of the aponeurosis of the external oblique, in the vicinity of the inguinal ring.

c.c.c.c. The aponeurosis of the external oblique muscle of the abdomen, divided along the crest of the ilium and the linea alba as far as the vicinity of the inguinal ring.

d. The left femoral arch.

e.e. The membrano-aponeurotic sheath of the cremaster muscle laid open.

f. Continuation of the sheath of the cremaster muscle, which contains the spermatic cord and the vaginal coat of the testicle.

g.g.g. The fibrous bundles of the cremaster muscle.

h.h. Soft cellular substance, interposed between the sheath of the cremaster and the proper hernial sac.

i.i. The hernial sac formed by the peritoneum.

k.k. A portion of omentum protruded and descended into the hernia.

l.l. The aponeurotic sheath of the rectus muscle of the left side, opened and turned back.

m. The great sac of the peritoneum, with the intestines shining through it.

o.o. The left rectus muscle of the abdomen laid bare, and turned very much towards the right side of the abdomen.

See page 653.

p. The internal oblique muscle of the abdomen of the left side.

q. A portion of the great sac of the peritoneum, which, after dividing the aponeurosis of the fascia-lata, and raising the fallopian ligament, appeared externally under the left femoral arch

r. Common integuments of the scrotum.

1. Femoral artery.

2. Femoral vein.

3. Circumflex iliac artery.

4. Origin of the epigastric artery.

5, 6, 7, 8. Continuation of the left epigastric artery, behind the neck of the hernial sac, towards the rectus abdominis muscle of the same side.

9. The origin of the epigastric vein.

10, 11, 12. Continuation of the epigastric vein behind the neck of the hernial sac, towards the rectus abdominis muscle.

13. The saphena vein.

14. Anterior crural nerve.

A. Glutæus maximus muscle.

B. The tensor vaginæ femoris.

C. The aponeurotic sheath of the thigh.

D. The sartorious muscle.

E. The rectus muscle of the thigh.

F. The vastus externus.

G. The iliacus internus.

H. The tendinous origin of the adductor muscles of the thigh.

I. The gracilis.

Fig. 3.

aa. A loop of ileum protruded at the left groin.

b. The omentum adhering to the inner side of the neck of the hernial sac.

cc. The edge of the omentum which did not adhere, turned back on the outer side of the hernial sac.

d. The omentum surrounding the protruded intestine and producing strangulation.

g. The bottom of the hernial sac.

h. The external covering of the hernia, formed by the membrano-aponeurotic sheath of the cremaster muscle.

ii. The vaginal coat of the testicle laid open.

k. The testicle.

l. The epididymis.

Fig. 4.

a.a. The aponeurosis of the external oblique muscle.

b.b. cc. The hernial sac laid completely open.

d.d. Constriction of the sac a little below its middle.

e. The superior cavity of the hernial sac.

f. The inferior cavity of the hernial sac.

ggg. The deep fossa of the superior cavity of the hernial sac.

hh. Marks the bottom of the inferior cavity of the hernial sac behind the testicle.

ii. Membrano-aponeurotic expansion of the cremaster, lying over the tunica vaginalis testis.

ll. The vaginal coat of the testicle laid open.

m. The testicle.

See pages 648, 656.

PLATE 3. T.

This plate represents congenital hernia.* It is produced by the intestine slipping down, from the communication betwixt the general cavity of the peritoneum, and the cavity of the tunica vaginalis.

a A portion of ileum which has fallen from the cavity of the abdomen into the tunica vaginalis.

b. Intestines within the cavity of the abdomen.

c. Peritoneum.

d. Tunica vaginalis.

e. Testicle.

f. Integuments of the scrotum.

g. Integuments of the abdomen.

* See page 677.

a

W.P. Cock

Fig 1.

Fig 2.

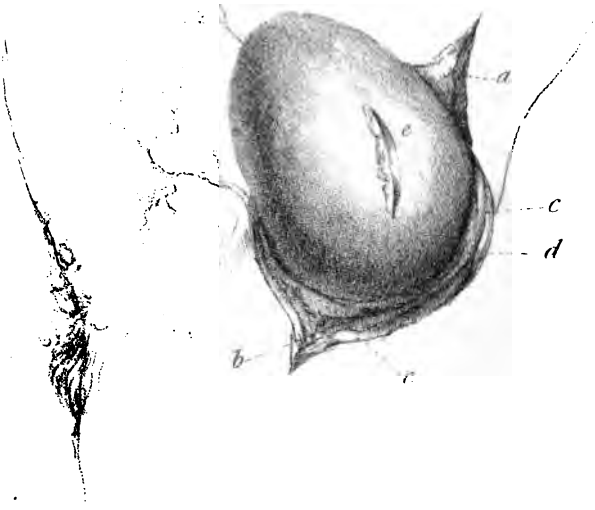

W.P. Cocks.

PLATE 4. T.

Fig. 1.

Represents the operation for hernia, descending into the labium of the woman.

a.b. The extent of the herniary tumour.

c. From this to B, is the course of the first incision, which cuts through the skin and cellular membrane, and exposes the fascia.

d. The fascia which covers the proper sac of the hernia. After dissecting off some lamina from it, it is pinched up by the forceps, and the knife being carried horizontally on the surface of the tumour, this layer is cut through; then the directory is pushed under it.

e. The directory pushed under the fascia, to ascertain its nature. Along this the knife is run, laying open the proper peritoneal sac.

f. The peritoneal sac, smooth; with distinct vessels running into it, and so transparent that the intestine gives it a darker hue.

Fig. 2.

The manner in which the femoral hernia will sometimes rise from the depth of the groin, when freed of the integuments, and binding of the fascia.

a.b. The extent of the incision of the integuments.

c.c. An aponeurosis dissected off the proper sac.

d. The hernia covered by the proper sac, the tumour is of a pyramidal form.

e. A cut through the sac.

See page 658.

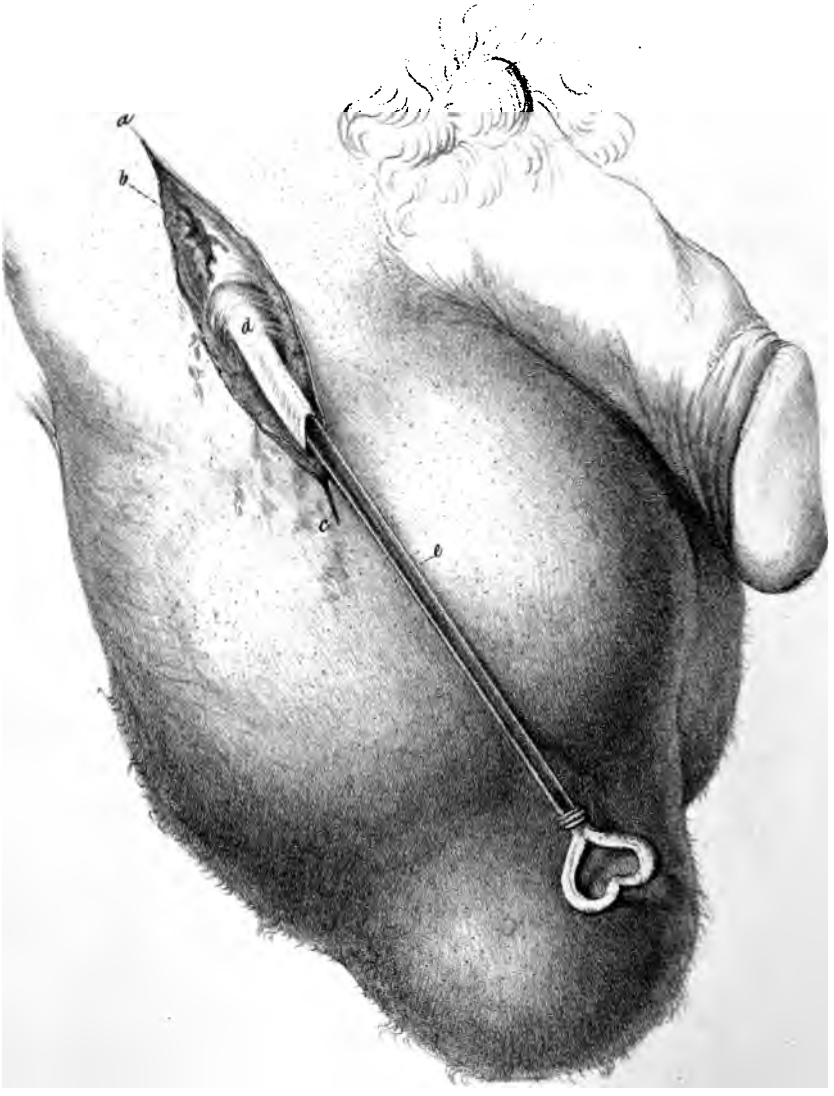
a
b
d
c
e

PLATE T. 8.

Scrotal Hernia.

A large scrotal hernia, where the incision has been made, of the proper size and direction, *a. c.* through the integuments.*

b. Shews the fat and cellular substance lying under the skin.

d. The aponeurosis, in which a small opening has been made for the introduction of a director, on which the aponeurosis is to be slit open further.

e. The director.

* The incision through the skin should be made just opposite the upper part of the external abdominal ring, and carried down to the inferior part of the tumour, unless the swelling be of a large size.

See pages 661 to 667.

W. P. Cocks.

PLATE T. 9.

Represents a portion of strangulated intestine.

The first stage of strangulation is exhibited in a dark red colour, with the veins turgid and distinct.

The second is shewn by a darker brown, with somewhat of a purplish tint, and the disappearance of the blood-vessels on the surface.

Mortification is distinguished by a more lurid brown colour, and no fluid blood appearing when the surface is touched with the lancet. It is confirmed when dark spots of a bluish-green are seen upon it, and when the surface is rough and soft.

See page 664.

PLATE T. 9 a.

Represents a process growing from the ilium, which passed around, and so greatly compressed a portion of the small intestines, as to prove the cause of death.

a. & *b.* Represent a Processus Cæcus, which passed and strangulated the portion of intestine marked by the letters *d.d.d.*

c. The ligament *c.* unites the above-mentioned unusual process of mesentery.

See page 664.

T. Plate 2.a

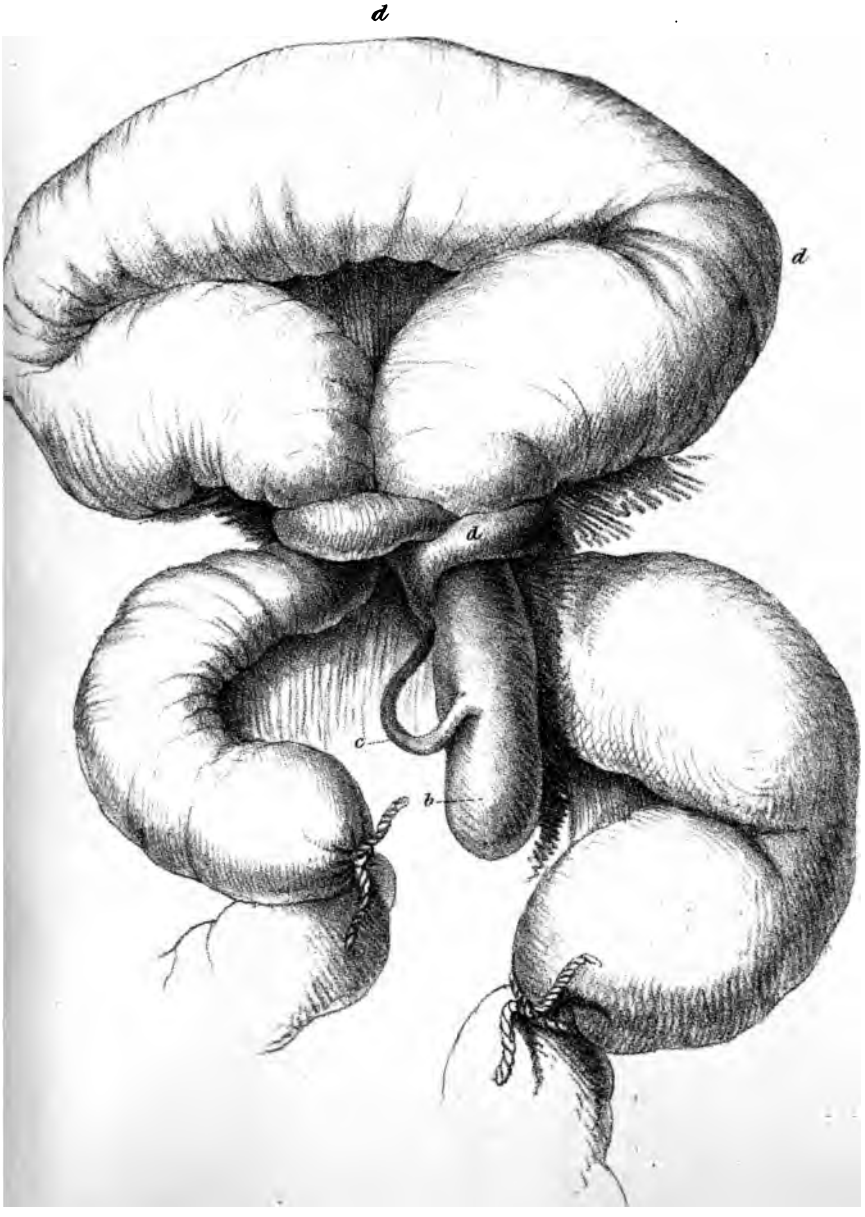

Fig 1

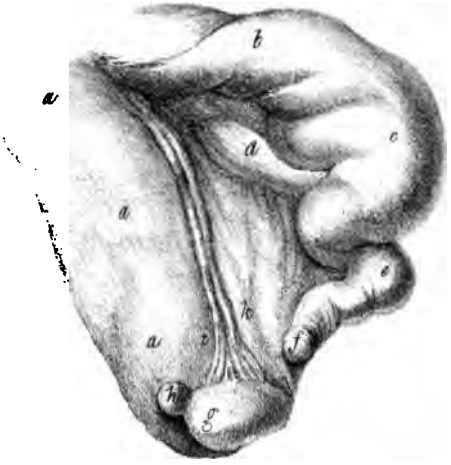

Fig 2.

W^P Cocks

PLATE 10. T.

Fig. 1.

The hernial sac being laid open, and the intestines turned back, an adhesion of the appendicula vermiformis to the sac and testicle is seen.

a.a.a. The production of peretonium that formed the hernial sac.

b. The colon.

c. The cœcum.

d. The ileum.

e. The appendicula vermiformis.

f. The firmish apex of this appendix adherent to the sac and testicle.

g. The testicle.

i. The spermatic vessels.

h. The epididymis.

k. The vas deferens.

Fig. 2.

a.a. Portion of omentum contained in a congenital inguinal hernia.

b. The testicle.

c. The epididymis.

d. A part of the omentum changed into a cylindrical mass.

e.e.e. Appendices of the omentum.

f.f. Intimate adhesions of the omentum to the bottom of the hernial sac, which here consists of the tunica vaginalis testis.

Fig 1.

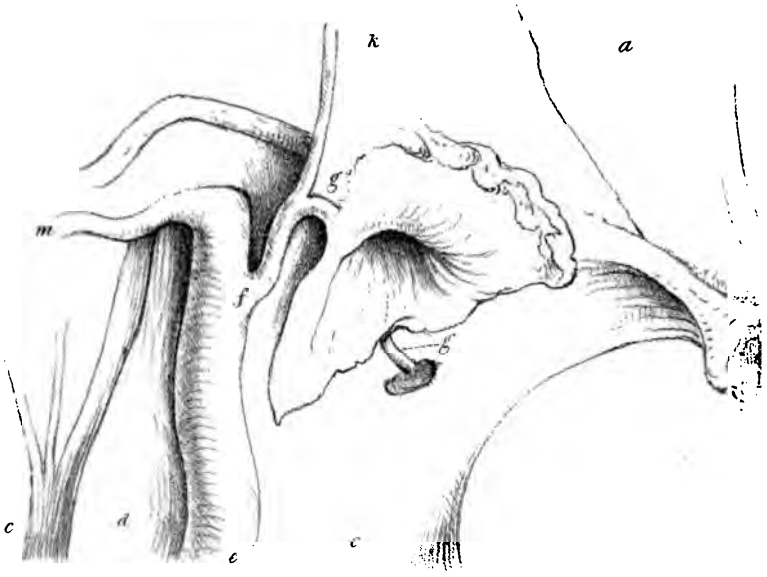

Fig 2

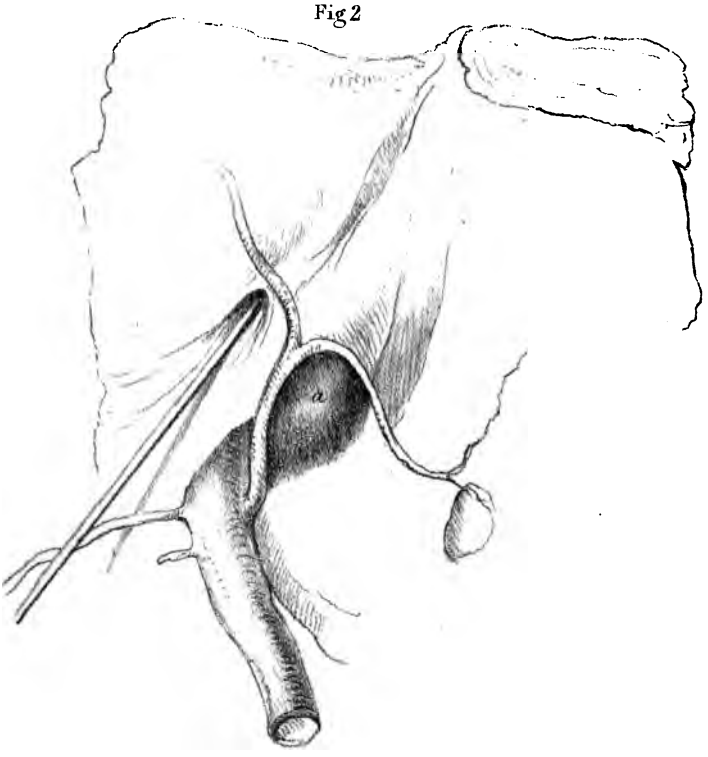

PLATE 15. T.

This plate is intended to exhibit the relative situation of the epigastric and obturator arteries, in respect to a crural hernia.

Fig. 1.

Shews a short trunk common to the epigastric and obturator arteries, which is situated on the ilial side of a crural hernia.

a. The abdominal muscles turned forwards.

b. The under part of the rectus abdominus.

c.c. A part of the iliacus internus muscle.

d. A part of the psoas muscle.

e. The anterior iliac artery. In this case the obturator and epigastric arteries arose from the common *f.*

g. The obturator artery passing behind, and then on the ilial side of the neck of the hernial sac, to the foramen obturatorium *i.*

k. The epigastric artery passing on the ilial side of the hernial sac, and crossing the round ligament of the womb.

m. The circumflex artery, passing outwards towards the os ilium.

See page 672, 674, 675.

Fig. 2.

Shews a long trunk common to the epigastric and obturator arteries, marked letter *A.*, sweeps along the ligament of Gimbernat, in its course to the foramen obturatorium.

PLATE T. 18.

---

a. The superior portion of the ileum.

b. The inferior portion of the ileum.

c.c.c. The ileum laid open, including that portion of it which had been strangulated by the neck of the hernial sac.

d. The promontory formed by the approximation of the two portions of the intestines, *a. b.* in a line parallel to each other.

e. Deep depression of the superior portion of the ileum above the promontory.

f.g. The furrow, by which the feculent matter descends from the superior orifice of the intestine into the membranous funnel, after the separation of the gangrened portion of the strangulated intestine.

h. The continuation of the internal membrane of the intestine.

i.i. The seat of the strangulation caused by the neck of the hernial sac.

k.k. The hernial sac, after the removal of the aponeurotic sheath of the cremaster, changed in texture, in consequence of the preceding inflammation.

l. The spermatic cord.

m.m. The vaginal coat stripped of the aponeurotic sheath of the cremaster.

n. The epididymis.

o. The testicle.

See page 206.

W P Coc

PLATE T. 19.

Congenital Umbilical Hernia.

a.a. The integuments around the navel covering the tumour.

b.b.b. External covering of the hernia, consisting of the cellular substance, which connects the umbilical vessels together the whole length of the cord.

c.c. The hernial sac formed by the peritoneum.

d. A portion of the liver, of a cylindrical shape, protruding at the umbilical ring, and contained in the hernial sac.

e.e. The umbilical vein, covered by the same kind of cellular texture which invests the funis.

f. The umbilical artery of the left side, larger and more developed than common, the right one being entirely wanting in this subject.

h. The umbilical cord.

See page 680.

PLATE T. 20.

Umbilical Hernia in a young Subject.

a.a.a.a. Layer of cellular substance, which, together with the delicate tendinous expansion over the abdominal muscles, formed the second covering of the hernia, immediately under the skin.

b.b. The hernial sac formed by the peritoneum.

c.c. The small intestine included in the hernial sac.

d. The linea alba.

e.e. The rectus muscle.

f.f. External oblique muscles.

See pages 680 to 683.

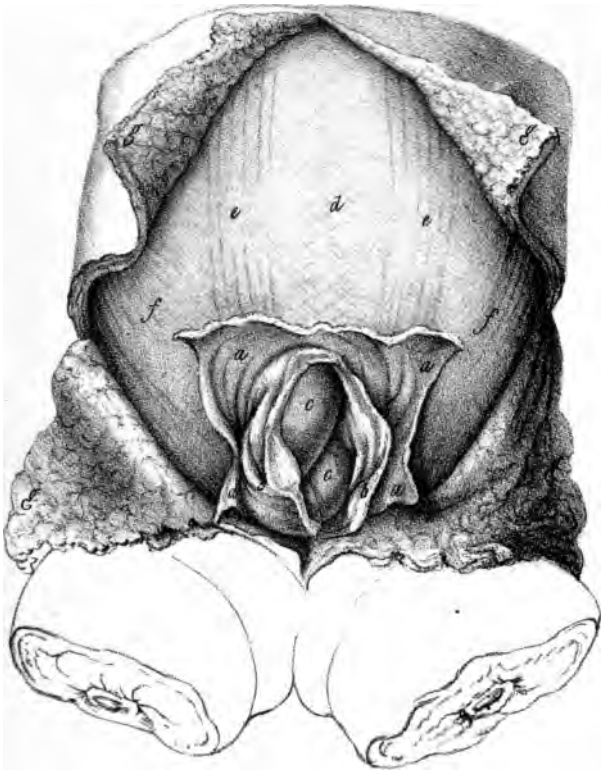

W. Cocks.

Fig. 1.

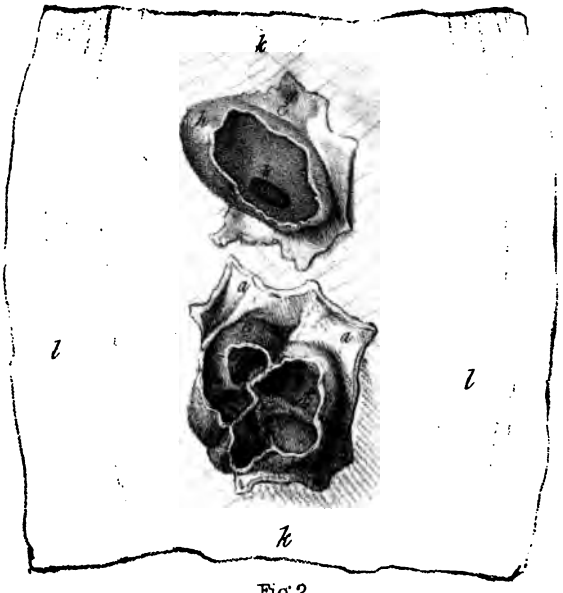

Fig. 2.

W^P Cocks.

PLATE T. 21.

Two Herniæ in an Adult.

Fig. 1.

This plate represents a true exomphalos, and a hernia of the linea alba in an adult, a little above the umbilicus.

a.a. The cellular tissue which covered the hernia immediately under the skin.

b. The aponeurotic aperture of the umbilicus of a round form.

c.c. The hernial sac formed by the peritoneum.

d.e.f. Divisions of the hernia.

g. The hernia of the linea alba. A cellular layer lying over the hernial sac.

h. The hernial sac formed by the peritoneum.

i. The oval fissure in the linea alba.

k.k. The linea alba.

l.l. The recti muscles of the abdomen.

See pages 683, 684.

Fig. 2.

Congenital umbilical hernia in the embryo.

a. The funis.
b. The hernia.

See page 680.

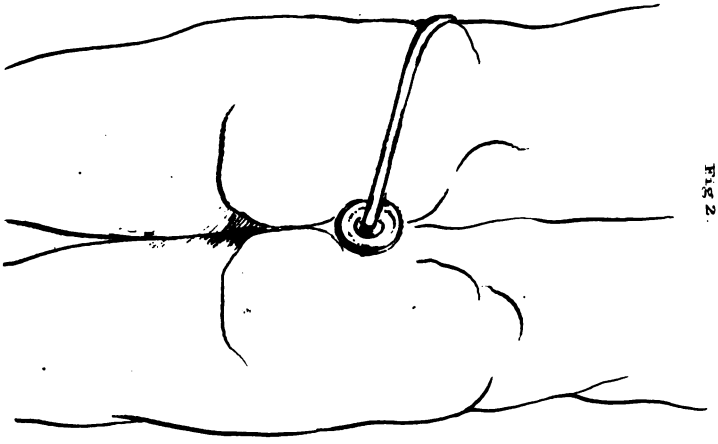

Fig 2.

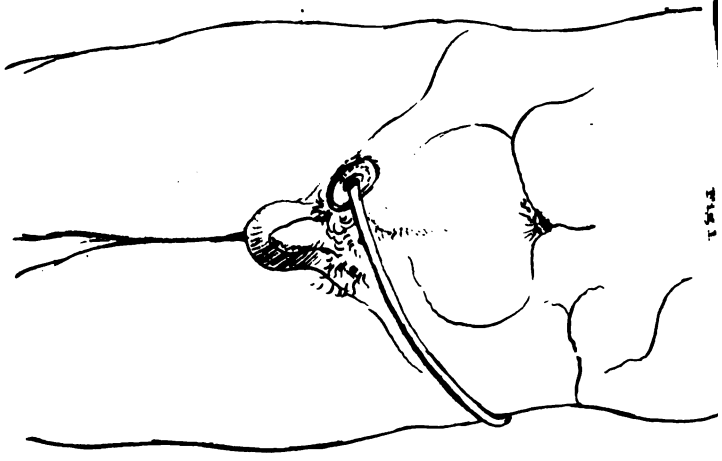

Fig 1.

PLATE T. 29 a.

Truss for a Single Inguinal Hernia.

This sort of truss is called "opposite sided," because the spring is (contrary to the common construction of trusses) made to apply on the opposite side to that on which the complaint is situated; that is to say, if the complaint is in the left groin, then the spring is placed on the right hip, and the front cushion brought across the centre of the body and placed with its lower edge just above the pubes. The back cushion should then be situated exactly on the spine. If the complaint be in the right groin, then the same truss will equally apply, but must be placed on the left hip, and continue across the body to the seat of complaint.

Fig. 1.

Front view of the body, with the truss applied as for a complaint on the right side.

Fig. 2.

Back view of the same.

See page 646.

PLATE T. 29 b.

Truss for a Double Inguinal Hernia.

The "Truss," with two pads, is for ruptures on both sides. To apply it the front cushions must be placed just above the bone of the pubes, and the back cushion on the centre of the back, and when placed, the small strap in front is used to keep the cushions at due distance from each other, but not to be made tight.

Fig. 1.

Front view of the body, with the truss applied.

Fig. 2.

Back view of the same.

See page 644.

Fig 1.

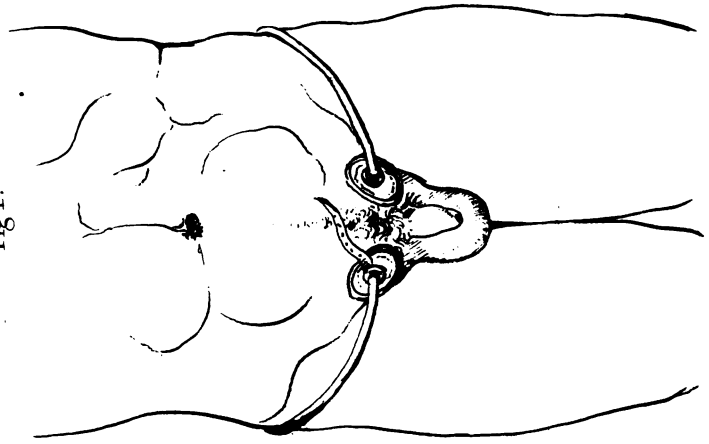

Fig 2.

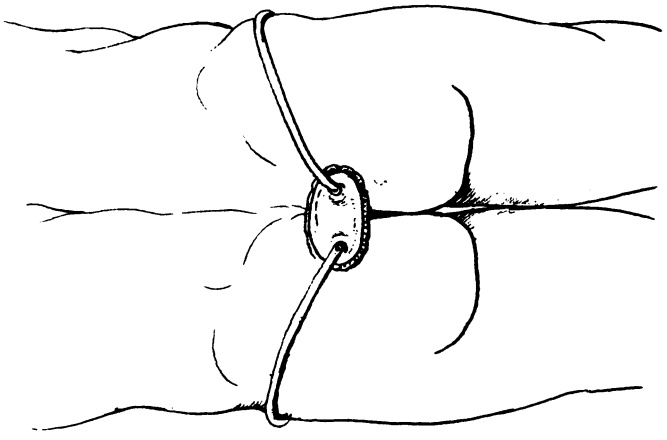


W.P. Cockes

PLATE 1. Sup.

This figure is an accurate representation of an old African negro, who had been the subject of elephantiasis for twenty years.

The skin, covering the lower portion of the abdomen and lower extremities, was indurated, and on different parts of its surface, were to be seen clusters of minute hard scales. The natural appearance of the legs and feet was destroyed by the enormous distension of the cellular tissue of the parts. The soles of the feet were covered with a substance of a horny texture, one-fifth of an inch in thickness. This poor fellow was very slow in his movements from the extreme rigidity of the lower limbs.

SYMPTOMS.

In general this affection manifests itself in a sudden and unexpected manner, without having been preceded by any premonitory symptoms; the patient experiences a violent pain, which gradually extends itself along the course of the lymphatic vessels, in a short time a kind of hard, tense chord, here and there interrupted by nodosities, may be felt. This chord is often exceedingly painful when touched,

and usually terminates at some of the large glands, as those of the groin or axilla, which become enlarged. When the disease, (as is commonly the case), attacks the limbs, the affected part becomes the seat of an erysipelatous inflammation, the cellular tissue itself inflames, and considerable swelling ensues. These symptoms are attended with general phenomena; fever takes place; there is much thirst, nausea, and vomiting, accompanying a prolonged chill, to which a violent heat of skin, or even copious sweats succeed; sometimes the brain is sympathetically affected, and the patient is seized with delirium. All these symptoms, with the exception of a slight swelling, entirely cease, and again return at uncertain intervals. At the end of every exacerbation the erysipelatous redness which occurs on the course of the lymphatic vessels disappears; but each time the swelling increases, and lasts after all the other symptoms have ceased, so that at the end of a certain period, of some months for instance, the affected parts present an engorgement, which, although it is at first soft, gradually becomes so hard as to resist the impression of the fingers. The disease thus goes on for some time; at last it stops, and may remain stationary during several years.

It now manifests all those characters which constitute it, and gives to the parts in which it is situated, a deformed and frightful appearance. Sometimes there is a uniform swelling of the arm or leg, which not only disguises all the prominencies of the limb, but may even cover part of the hand or foot, falling over them in folds; these parts seem as if they were in a state of atrophy; at other times, the tumour is unequal, the swellings are deformed, and separated from each other by deep fissures, giving an extraordinary and hideous aspect to the limb. Again, the disease has a tendency to attack fresh surfaces, and although at first developed on the fore-arm or leg, it gradually extends over the whole limb. The cellular tissue continues to alter, and is at last converted into a misshapen, fungous mass.

The skin, which, as we have stated, is not at first affected, may now assume different appearances; thus, it may remain entirely sound, and only present a whiter colour, and great firmness; at other times, the subcutaneous veins, much distended and enlarged, traverse it in all directions, causing a multitude of varicose tumours, which give it a violet-colour; but this membrane may also undergo real alterations. It often becomes the seat of an erysipelatous, or even vesicular inflamma-

tion; in the latter, a slight effusion of lymph occurs, followed by small, thin, soft, yellow scales; it may, on other occasions, gradually increase in roughness, and present scales similar to those of Ichthyosis, or even become studded with small, soft, fungous vegetations; and finally, under some circumstances, it is divided by fissures, cracks, and ulcerations, which are afterwards covered by thick, yellow scabs.

The lymphatic glands, after having remained hard and scirrhous, may sometimes suppurate, or be struck with gangrene. Indolent abscesses, which give rise to deep, fœtid, copious suppurations, occur at this time throughout the enormously distended limb.

MORBID ANATOMY.

The skin is generally hardened, sometimes covered with yellowish scales or thick scabs, or it may be chapped, and present small, hard scales, analogous to those of Ichthyosis. 1st. The epidermis is very thick, chapped, and adherent. 2nd. The mucous tissue is very distinct, and, according to the observations of Andral, he

was able to recognize the different layers described by Gaulthier, and afterwards by Dutrochet, between the epidermis and true skin. 3d. The papillary tissue is very much developed, and distinct from the dermis; the papillæ are elongated, enlarged, and prominent, according to Andral and Chevalier. 4th. The dermis is of considerable volume, and is sometimes in such a state of hypertrophy, as to exceed half-an-inch in thickness. 5th. The cellular tissue is much developed, and sometimes contains a semi-fluid, gelatinous matter in its cells; but it is most generally hardened, slightly scirrhous, and is denser in proportion as it is nearer to the dermis. The muscles are usually pale, discoloured, softened, and much diminished in size. Sometimes the veins are obliterated.

TREATMENT.

Elephantiasis of the Arabs. At the commencement, the inflammation of the lymphatic vessels should be combated by antiphlogestics and emollients; if it is very extensive, recourse must be had to venesection; the application

of leeches along the course of the inflamed vessels, will often be very successful; these are not to be placed immediately over the seat of the inflammation, but a little on each side of it; large emollient cataplasms may also be used. When the disease is in a chronic state, (the usual form in which it is seen) it presents many more obstacles to a cure; bloodletting has been highly praised, but it is far from fulfilling the high character that has been attributed to it.

Blisters and caustics have also failed in a majority of cases; the same may be said of the mercurial preparations.

Compression is one of the best remedies in this complaint. It should be made with a bandage of two or three fingers in breadth and drawn tolerably tight. It generally reduces the tumefaction very rapidly, and even if it does not entirely restore the affected parts to their natural condition, it facilitates the use of other means.

As to internal treatment, it is in most cases entirely nugatory, though in some cases the administration of purgatives has produced advantageous effects.

PLATE A. A. 10.

Fungus Hæmatodes arising from the thigh-bone in consequence of fracture.

See page 541.

PLATE A. A. 10 a.

Fungus hæmatodes arising from the cancelli of the tibia. The tumour was soft, elastic, and of the size of an orange.

See page 541.

W. Cock

Fig 1. *a.a. Plate.*

Fig 2

PLATE 11. a. a.

Fig. 1.

An enlarged Parotid Gland.

The parotid gland is the largest of the salivary glands. It is situated partly before and partly beneath the external ear, filling up the deep excavation on the sides of the face, between the posterior edge of the ramus of the lower jaw, the meatus auditorius externus, and the mastoid process of the temporal bone. It extends vertically from the zygomatic arch to the angle of the jaw. Its form is that of a very irregular pyramid, with an oval base directed outwards. Anteriorly, between the jaw-bone and the gland, we find, from above downwards, the superficial temporal artery and vein; then the facial nerve, which crosses the vessels opposite the neck of the condyle, embedded in the deep granules of the gland; next, the facial, or transverse facial, arteries; several veins of considerable volume, which ramify in the secretory tissue; finally, the cervico-facial branch of the respiratory nerve

of the face, (portio-dura) the termination of the stylo-maxillary ligament, and the masseter.

Posteriorly, the parotid gland is somewhat firmly fixed, from above downwards, and from before backwards, first, to the auditory canal, then to the fore part of the mastoid process and the anterior edge of the sterno-mastoid muscle; between the ear and the mammoid process it covers the posterior auricular artery; upon the apex of this apophysis, and externally, it lies upon another artery, which is sometimes larger than the preceding. Internally, or deeply, it rests upon the trunk of the facial nerve, and the three filaments which are detached from it at its exit from the stylo-mastoid foramen; then upon the styloid process and the musculo-fibrous bundle, arising from it; upon the digastric muscle; then, a little farther forwards upon the styloidien artery, upon many anonymous twigs which penetrate the glandular lobules, and are lost in their substance; upon the trunk even of the external carotid; behind which the gland sends a process, which sometimes dips very deep, and is applied upon the glosso-pharyngeal nerve, the internal jugular, and internal carotid.

In this situation, the gland and the arteries are so intimately connected, that it is almost impossible to remove the one without wounding the others. The occipital and inferior pharyngeal

arteries are likewise covered by the parotid; which, on the other hand, is finally prolonged between the pterygoid muscles and the styloid process as far as the pharynx, passing between the external carotid and the stylo-maxillary ligament. In the latter direction, this gland is continuous with the submaxillary.

These are the complicated, numerous, and important relations, which render the total extirpation of the parotid gland so dangerous, and almost impossible.

See pages 1126, 1127.

Fig. 2.

An enlarged Thyroid Gland.

On the sides of the trachea and larynx is situated a soft, spongy, and exceedingly vascular mass, called the thyroid gland, though it does not possess any excretory duct, or elaborate any appreciable secretion.

This body exhibits great differences in its size in different individuals, and at different ages in the same individual, without our being able to assign any reasons for them; but, in general, it is larger in the child than in the adult, and in the female than in the male.

It is formed of two ovid lobes, flattened from before backwards; thicker inferiorly than superiorly; and united above by a transverse portion, named the isthmus of the thyroid gland, and which varies much in extent. Sometimes they are united, and form one large lobe. The anterior surface of the gland is convex, and covered by one of the laminæ which form its cellulo-aponeurotic envelopment, and by the

sterno-thyroid and sterno-hyoid before the platysma, omo-hyoid, and sterno-mastoid, muscles laterally; these are covered by the fasciæ of the neck and the skin. When the thyroid gland becomes the seat of a tumour, the size of which increases slowly, this musculo-aponeurotic layer gradually yields, and only slightly compresses it; but the case is not the same when the progress of the disease, instead of being chronic, as in goitre, etc., is acute, as in inflammation of this part. In fact, this membrane then strongly opposes the development of the tumour, throws it backwards, and, when it is of considerable size, produces very great difficulty in respiration and deglutition. The part of the gland which is the seat of the disease, has also a very marked influence on the severity of the symptoms. Thus, enlargement of the right lobe does not produce such serious symptoms as that of the left lobe or the middle portion. When the left lobe is affected, the patient complains more of a difficulty in deglutition than of dyspnœa, whilst the contrary is the case when the middle portion is affected.

The posterior surface of the gland is concave, and united to the larynx and the superior part of the trachea by means of cellular tissue; it also covers the crico-thyroid, thyro-hyoid, and inferior constrictor muscles of the pharynx.

Its lateral edges are in contact with the common carotid arteries, the pneumo-gastric and inferior laryngeal nerves, and the anastomosing branches from the cervical-ganglia; and lastly, but on the left side only, with the œsophagus, which explains why the deglutition is more impeded when the left lobe is enlarged, than when the disease is on the opposite side.

The thyroid gland receives four arteries of considerable size (the superior* and inferior thyroideal). The first arises from the external carotid, opposite the cornua of the os hyoides, but sometimes lower down. It runs upwards and inwards, then bends downwards towards the thyroid gland, in an arched manner, convex superiorly. It soon divides into several branches, which pass beneath the different muscles of the larynx; but the trunk is at first superficial; the lingual nerve lies superior, and the laryngeal nerve posterior to it. Its

* *Operation.*—The trunk of the superior thyroid artery may be readily exposed and tied, either in the direction of a line drawn from the cornu of the os hyoides to the anterior and inferior part of the thyroid cartilage, or by making an incision obliquely downwards and outwards, from the os hyoides to the sterno-mastoid muscle; or, lastly, by dividing the parts in the omo-hyoid triangle parallel to the sterno-mastoid muscle. In this space, in fact, the artery, before it reaches the gland, is covered only by the ramus descendens noni, some veins, the aponeurosis, and the common integuments.

branches are the ramus hyoideus, ramus superficialis, ramus laryngeus, ramus thyroideus.

The inferior thyroid artery* comes from the subclavian; at first, it mounts vertically upon the anterior scalenus, and having reached the level of the fifth vertebra, it makes a sudden turn inwards; it then passes transversely behind the common carotid, following the same course as the omo-hyoideus, and arrives at the inferior and external part of the thyroid gland, after having given off the ascending cervical artery and a few twigs. It then divides into two large branches, which pass behind the gland and anastomose with the superior thyroid arteries, and the inferior of the opposite side.

* *Operation of tying the inferior Thyroid Artery.*—The integuments must be divided along the anterior edge of the sterno-cleido-mastoid muscle; and push to one side the cellulo-aponeurotic sheath which encloses the carotid; we then seek for the inferior thyroid artery, a little under and behind the omo-hyoid muscle. In applying the ligature, the two principal nerves which pass before and behind the vessel must not be included; consequently, we must vary the method according to the position of the parts. If the nervous trunks are very close to the trachea, the needle must be passed from below upwards, and from within outwards; if these nerves are nearer the carotid, we should pass it in the opposite direction.

See page 1095.

Operation for removing the Thyroid Gland.

An incision of an elliptical shape, if the tumour be large, or if the integuments be diseased, is to be made over it, with the long diameter directed from above to below. The surface of the swelling is next to be uncovered by dissecting back the integuments on both sides; then the finger is to be insinuated between the skin and the muscles, pushing it upward and backward, till it comes in contact with the thyroid artery, round which a ligature is to be passed with a blunt needle. In a similar manner, the other superior thyroid artery, and the two inferior vessels, are to be secured, when the whole gland is to be removed. By these ligatures we cut off the circulation into the tumour, and, consequently, are left at liberty to finish the operation by cutting the vessels nearer to the morbid parts than where the threads have been applied, and by dividing the sterno-hyoid and thyroid muscles, above and below the tumour, which is afterwards to be detached from the trachea and gullet, by cautious working with the fingers. In this way, we may remove one or both lobes of the thyroid gland; but the operation is difficult, tedious, and not without danger.

Fig 1.

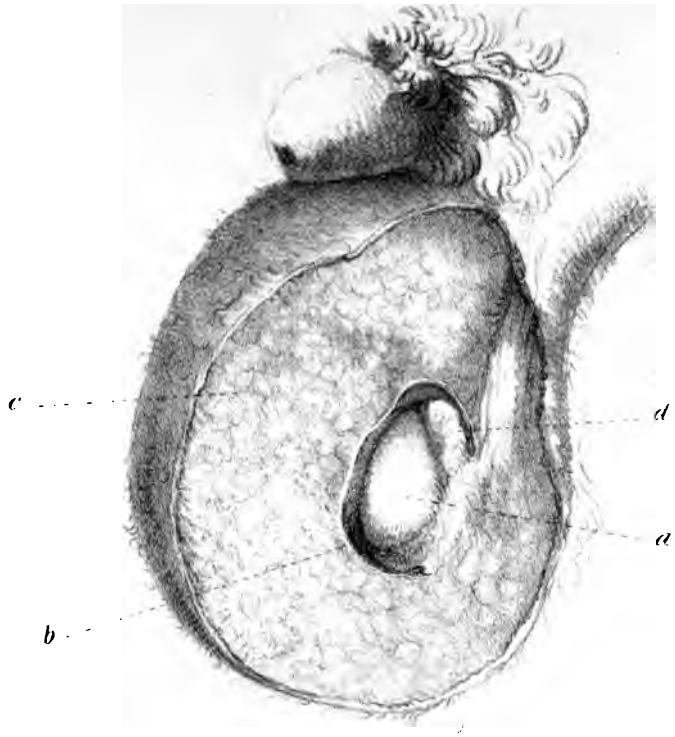

Fig 2

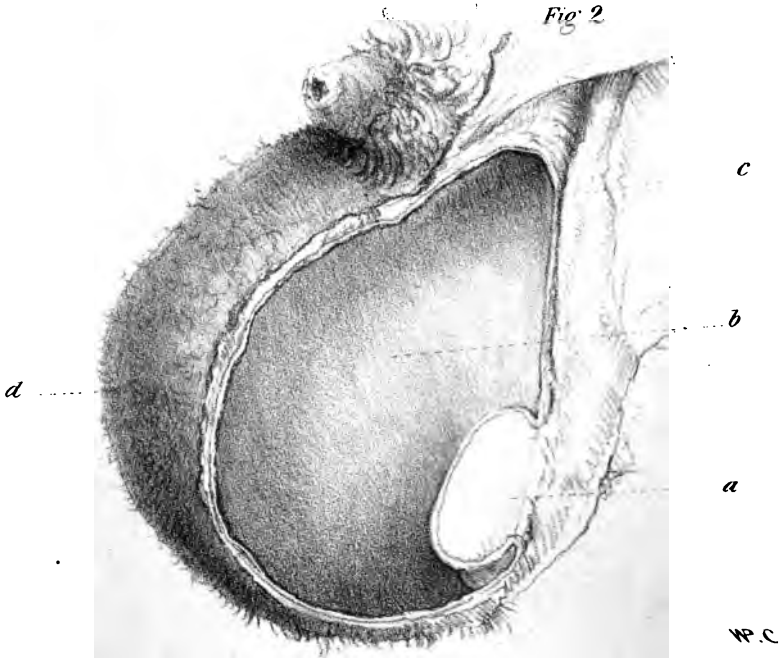

W.C.

PLATE V. 1.

An Anasarcous Tumour of the Scrotum and Hydrocele of the Tunica Vaginalis.

Fig. 1.

a. Testicle.
b. Tunica vaginalis.
c. An extensive effusion of serum into the cellular tissue of the scrotum.

* See page 705.

Fig. 2.

a. Testicle,
b. The tunica vaginalis distended with water.
c. Cellular membrane of the spermatic cord.
d. Integuments of the scrotum.

See page 707.

C. Plate

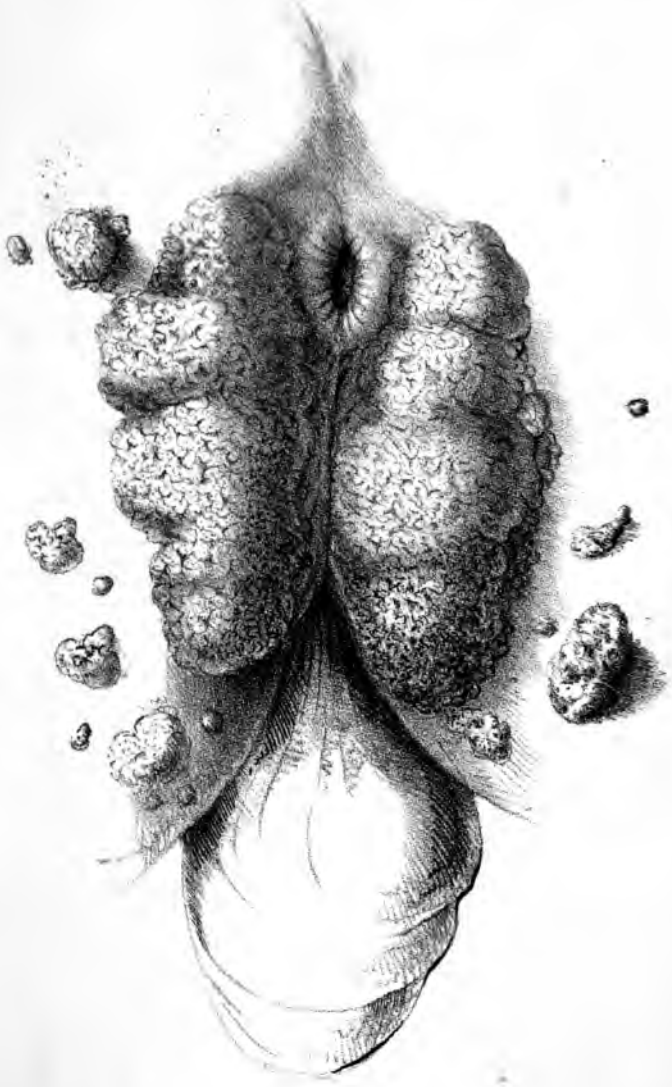

W. Coc

PLATE C. 3 a.

A large crop of warts, situated on the nates round the verge of the anus of a young man, labouring under gonorrhœa.

Warts are small sarcomata that offer the following varieties :—

Simplex . . . . . Simple Wart . . .	Simple and distinct; sesile or pensile.
Lobosa . . . . . Lobed Wart . . .	Full of lobes and fissures.
Confluens . . . . Confluent Wart .	In coalescing clusters.

See page 1250.